PLACE

PLATFORM OF LABORATORIES FOR ADVANCES IN CARDIAC EXPERIENCE

ROMA
Centro Congressi
di Confindustria
Auditorium
della Tecnica

9ª Edizione

30 Settembre
1 Ottobre
2022

Ten Minutes Answers in Cardiologia d'Urgenza

EMBOLIA POLMONARE

Andrea Ciolli

UOSD Cardiologia d'Urgenza
Ospedale Sandro Pertini, Roma

- 30-day all-cause mortality rates between 9 and 11%,
- 34% die within a few hours of the acute event,
- only 7% of patients who die early are correctly diagnosed

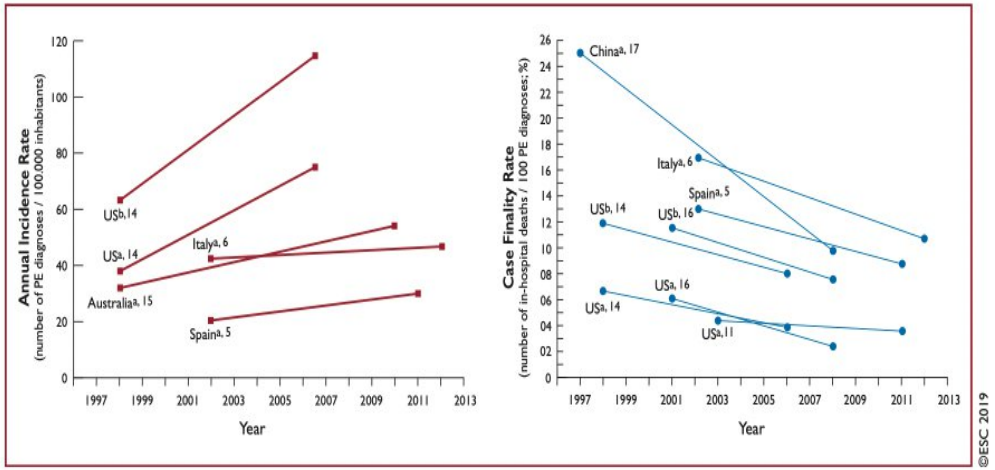

Figure 1 Trends in annual incidence rates (left panel) and case fatality rates (right panel) of pulmonary embolism around the world, based on data retrieved from various references.[5,6,11,14–17] Reproduced with permission from JACC 2016;67:976-90. PE = pulmonary embolism; US = United States.
[a]PE listed as principal diagnosis.
[b]Any listed code for PE was considered.

JACC 2016;67:976-90.

IN CASO DI SOSPETTA EP VA SEMPRE CONTROLLATO IL D DIMERO?

DIPENDE….

2019 ESC Guidelines for the diagnosis and management of acute pulmonary embolism developed in collaboration with the European Respiratory Society (ERS)

Recommendations for diagnosis

Clinical evaluation		
It is recommended that the diagnostic strategy be based on clinical probability, assessed either by clinical judgement or by a validated prediction rule.[89,91,92,103,134,170–172]	I	A

ASSESSMENT OF CLINICAL (PRE-TEST) PROBABILITY

PULMONARY EMBOLISM

10% in the low-probability category
30% in the moderate-probability category
65% in the high-probability category

Table 5 The revised Geneva clinical prediction rule for pulmonary embolism

Items	Clinical decision rule points	
	Original version[91]	Simplified version[87]
Previous PE or DVT	3	1
Heart rate		
75–94 b.p.m.	3	1
≥95 b.p.m.	5	2
Surgery or fracture within the past month	2	1
Haemoptysis	2	1
Active cancer	2	1
Unilateral lower-limb pain	3	1
Pain on lower-limb deep venous palpation and unilateral oedema	4	1
Age >65 years	1	1
Clinical probability		
Three-level score		
Low	0–3	0–1
Intermediate	4–10	2–4
High	≥11	≥5

2019 ESC Guidelines for the diagnosis and management of acute pulmonary embolism developed in collaboration with the European Respiratory Society (ERS)

Recommendations for diagnosis

D-dimer		
Plasma D-dimer measurement, preferably using a highly sensitive assay, is recommended in outpatients/emergency department patients with low or intermediate clinical probability, or those that are PE-unlikely, to reduce the need for unnecessary imaging and irradiation.[101–103,122,164,171,173,174]	I	A
D-dimer measurement is not recommended in patients with high clinical probability, as a normal result does not safely exclude PE, even when using a highly sensitive assay.[175,176]	III	A

AVOIDING OVERUSE OF DIAGNOSTIC TESTS

The pulmonary embolism rule out criteria (PERC rule)

Age <50 years
Heart rate <100 bpm
Oxyhemoglobin saturation ≥95%
No hemoptysis
No estrogen use
No prior DVT or PE
No unilateral leg swelling
No surgery/trauma requiring hospitalization within the prior four weeks

* This rule is only valid in patients with a low clinical probability of PE (gestalt estimate <15 percent).
In patients with a low probability of PE who fullfil all eight criteria, the likelihood of PE is low and no further testing is required.
All other patients should be considered for further testing with sensitive D-dimer or imaging.

Reference:

1.Kline JA, Courtney DM, Kabrhel C, et al. Prospective multicenter evaluation of the pulmonary embolism rule-out criteria. J Thromb Haemost 2008; 6:772.

UN D DIMERO NEGATIVO CONSENTE DI ESCLUDERE LA DIAGNOSI DI EP ?

DIPENDE….

PROBABILITA' BASSA

↓

PERC RULE

PROBABILITA' BASSA/INTERMEDIA

↓

D DIMERO

↓ NEGATIVO

↓ POSITIVO

↓

TC POLMONARE

PROBABILITA' ALTA

↓

TAC POLMONARE

IL D DIMERO E' UGUALE PER TUTTI ?

NO !

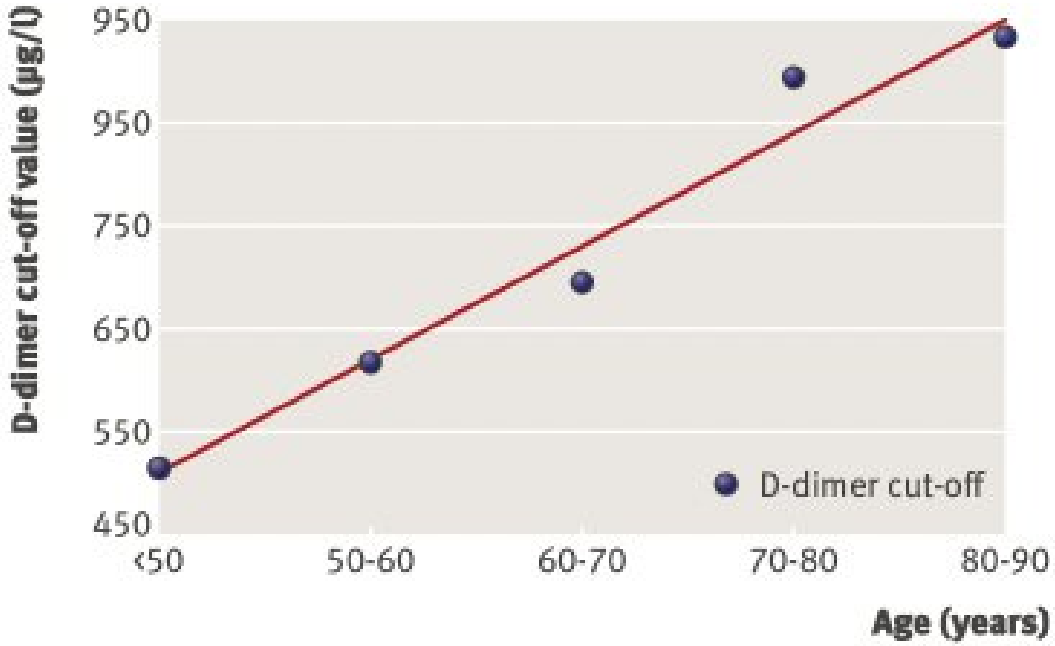

Fig 1 | Optimal cut-off values for D-dimer test for pulmonary embolism by age in patients with an unlikely clinical probability of pulmonary embolism (sensitivity set at 100%)

BMJ 2010;340:c1475
doi:10.1136/bmj.c1475

LA TAC DEL TORACE HA SEMPRE RAGIONE ?

QUASI SEMPRE

Table 5. Positive and Negative Predictive Values of CTA, as Compared with Previous Clinical Assessment.*

Variable	High Clinical Probability		Intermediate Clinical Probability		Low Clinical Probability	
	No./Total No.	Value (95% CI)	No./Total No.	Value (95% CI)	No./Total No.	Value (95% CI)
Positive predictive value of CTA	22/23	96 (78–99)	93/101	92 (84–96)	22/38	58 (40–73)
Positive predictive value of CTA or CTV	27/28	96 (81–99)	100/111	90 (82–94)	24/42	57 (40–72)
Negative predictive value of CTA	9/15	60 (32–83)	121/136	89 (82–93)	158/164†	96 (92–98)
Negative predictive value of both CTA and CTV	9/11	82 (48–97)	114/124	92 (85–96)	146/151†	97 (92–98)

* The clinical probability of pulmonary embolism was based on the Wells score: less than 2.0, low probability; 2.0 to 6.0, moderate probability; and more than 6.0, high probability. CI denotes confidence interval.

PIOPED II Investigators. Multidetector computed tomography for acute pulmonary embolism.
N Engl J Med 2006;354:2317 2327.

2019 ESC Guidelines for the diagnosis and management of acute pulmonary embolism developed in collaboration with the European Respiratory Society (ERS)

Recommandations for diagnosis

PROBABILITA' BASSA/INTERMEDIA

TAC NEGATIVA

NO EP

I	A

2019 ESC Guidelines for the diagnosis and management of acute pulmonary embolism developed in collaboration with the European Respiratory Society (ERS)

Recommandations for diagnosis

PROBABILITA' BASSA/INTERMEDIA

TAC NEGATIVA

↓

NO EP

I | A

PROBABILITA' INTERMEDIA/ALTA

TAC POSITIVA

↓

EP

I | B

2019 ESC Guidelines for the diagnosis and management of acute pulmonary embolism developed in collaboration with the European Respiratory Society (ERS)

Recommandations for diagnosis

PROBABILITA' BASSA/INTERMEDIA

TAC NEGATIVA

↓

NO EP

I | A

PROBABILITA' INTERMEDIA/ALTA

TAC POSITIVA

↓

EP

I | B

PROBABILITA' INTERMEDIA/ALTA

TAC NEGATIVA

↓

EP (?)

IIa | B

.. E SE LA TC EVIDENZIA DIFETTI SUB-SEGMENTALI ?

Further imaging tests to confirm PE may be considered in cases of isolated subsegmental filling defects.[115]	IIb	C

Planar V/Q scan	• Almost no contraindications • Relatively inexpensive • Strong validation in prospective management outcome studies	• Not readily available in all centres • Interobserver variability in interpretation • Results reported as likelihood ratios • Inconclusive in 50% of cases • Cannot provide alternative diagnosis if PE excluded	• Lower radiation than CTPA, effective dose ~2 mSv[b]
Pulmonary angiography	• Historical gold standard	• Invasive procedure • Not readily available in all centres	• Highest radiation, effective dose 10–20 mSv[b]

2019 ESC Guidelines for the diagnosis and management of acute pulmonary embolism developed in collaboration with the European Respiratory Society (ERS)

QUALE E' IL RUOLO DELL'ECOCARDIOGRAMMA NELLO SCREENING DIAGNOSTICO DELLA EP ?

1. ECHOCARDIOGRAM IS NOT MANDATORY AS PART OF THE ROUTINE DIAGNOSTIC WORKUP IN HAEMODYNAMICALLY STABLE PATIENTS,
2. IT MAY BE USEFUL IN THE DIFFERENTIAL DIAGNOSIS OF ACUTE DYSPNOEA,
3. <u>IN SUSPECTED HIGH-RISK PE THE ABSENCE OF ECHOCARDIOGRAPHIC SIGNS OF RV OVERLOAD OR DYSFUNCTION EXCLUDES PE</u>

A. Enlarged right ventricle, parasternal long axis view

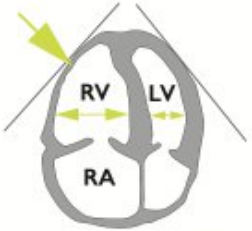

B. Dilated RV with basal RV/LV ratio >1.0, and McConnell sign (arrow), four chamber view

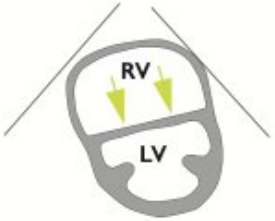

C. Flattened intraventricle septum (arrows) parasternal short axis view

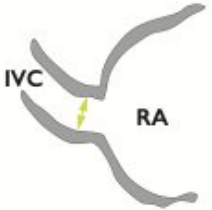

D. Distended inferior vena cava with diminished inspiratory collapsibility, subcostal view

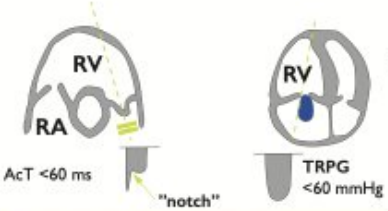

E. 60/60 sign: coexistence of acceleration time of pulmonary ejection <60 ms and midsystolic "notch" with mildy elevated (<60 mmHg) peak systolic gradient at the tricuspic valve

F. Right heart mobile thrombus detected in right heart cavities (arrow)

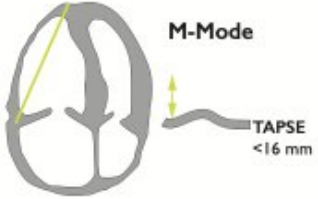

G. Decreased tricuspid annular plane systolic excursion (TAPSE) measured with M-Mode (<16 mm)

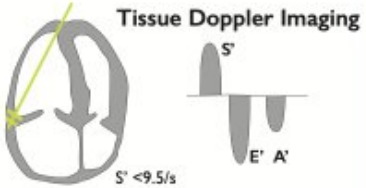

H. Decreased peak systolic (S') velocity of tricuspid annulus (<9.5 cm/s)

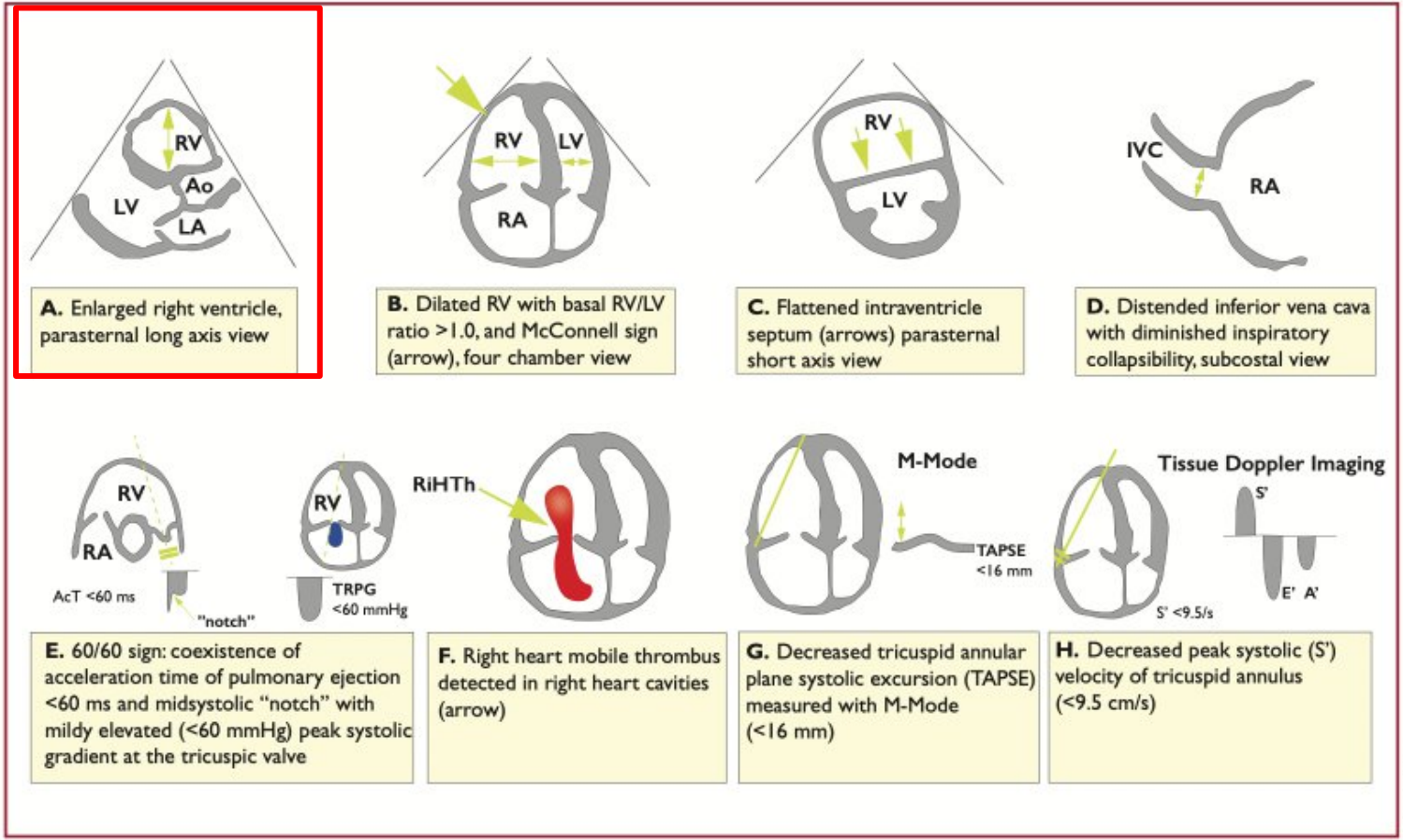

A. Enlarged right ventricle, parasternal long axis view

B. Dilated RV with basal RV/LV ratio >1.0, and McConnell sign (arrow), four chamber view

C. Flattened intraventricle septum (arrows) parasternal short axis view

D. Distended inferior vena cava with diminished inspiratory collapsibility, subcostal view

E. 60/60 sign: coexistence of acceleration time of pulmonary ejection <60 ms and midsystolic "notch" with mildy elevated (<60 mmHg) peak systolic gradient at the tricuspic valve

F. Right heart mobile thrombus detected in right heart cavities (arrow)

G. Decreased tricuspid annular plane systolic excursion (TAPSE) measured with M-Mode (<16 mm)

H. Decreased peak systolic (S') velocity of tricuspid annulus (<9.5 cm/s)

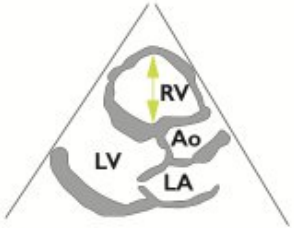

A. Enlarged right ventricle, parasternal long axis view

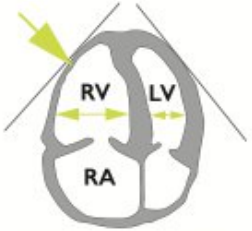

B. Dilated RV with basal RV/LV ratio >1.0, and McConnell sign (arrow), four chamber view

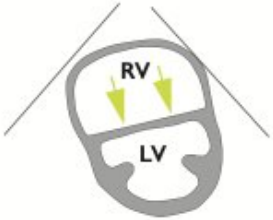

C. Flattened intraventricle septum (arrows) parasternal short axis view

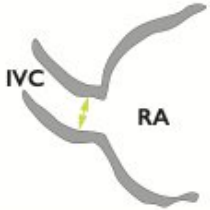

D. Distended inferior vena cava with diminished inspiratory collapsibility, subcostal view

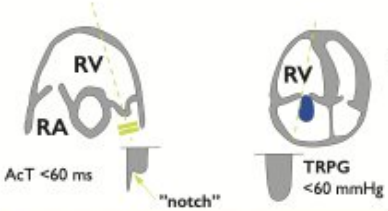

E. 60/60 sign: coexistence of acceleration time of pulmonary ejection <60 ms and midsystolic "notch" with mildy elevated (<60 mmHg) peak systolic gradient at the tricuspic valve

F. Right heart mobile thrombus detected in right heart cavities (arrow)

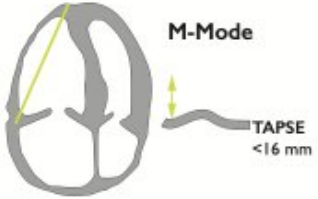

G. Decreased tricuspid annular plane systolic excursion (TAPSE) measured with M-Mode (<16 mm)

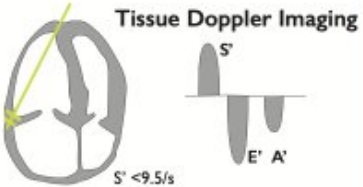

H. Decreased peak systolic (S') velocity of tricuspid annulus (<9.5 cm/s)

A. Enlarged right ventricle, parasternal long axis view

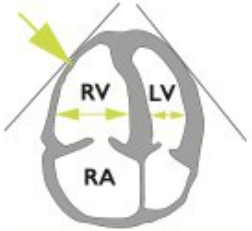

B. Dilated RV with basal RV/LV ratio >1.0, and McConnell sign (arrow), four chamber view

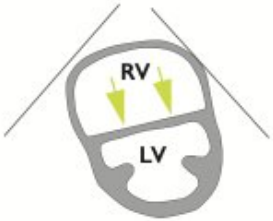

C. Flattened intraventricle septum (arrows) parasternal short axis view

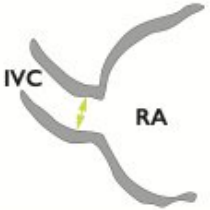

D. Distended inferior vena cava with diminished inspiratory collapsibility, subcostal view

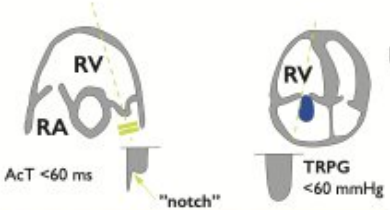

E. 60/60 sign: coexistence of acceleration time of pulmonary ejection <60 ms and midsystolic "notch" with mildy elevated (<60 mmHg) peak systolic gradient at the tricuspic valve

F. Right heart mobile thrombus detected in right heart cavities (arrow)

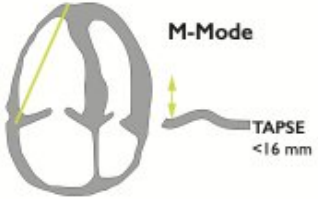

G. Decreased tricuspid annular plane systolic excursion (TAPSE) measured with M-Mode (<16 mm)

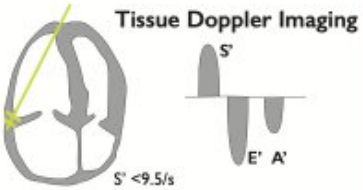

H. Decreased peak systolic (S') velocity of tricuspid annulus (<9.5 cm/s)

A. Enlarged right ventricle, parasternal long axis view

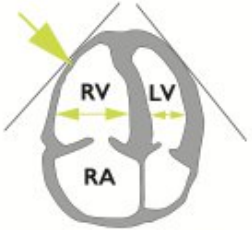

B. Dilated RV with basal RV/LV ratio >1.0, and McConnell sign (arrow), four chamber view

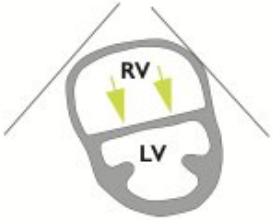

C. Flattened intraventricle septum (arrows) parasternal short axis view

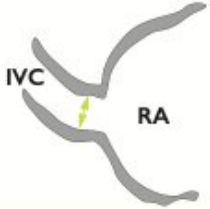

D. Distended inferior vena cava with diminished inspiratory collapsibility, subcostal view

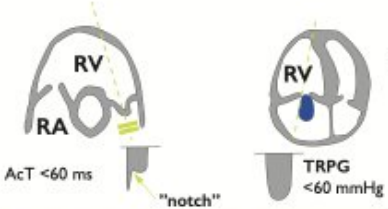

E. 60/60 sign: coexistence of acceleration time of pulmonary ejection <60 ms and midsystolic "notch" with mildy elevated (<60 mmHg) peak systolic gradient at the tricuspic valve

F. Right heart mobile thrombus detected in right heart cavities (arrow)

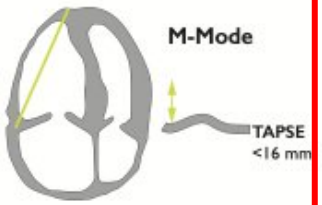

G. Decreased tricuspid annular plane systolic excursion (TAPSE) measured with M-Mode (<16 mm)

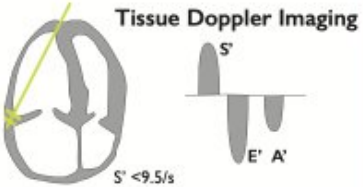

H. Decreased peak systolic (S') velocity of tricuspid annulus (<9.5 cm/s)

E CHE DIRE DELLA ECOGRAFIA COMPRESSIVA DEGLI ARTI INFERIORI

CENERENTOLA DELLA DIAGNOSTICA EP?

Lower-limb CUS		
It is recommended to accept the diagnosis of VTE (and PE) if a CUS shows a proximal DVT in a patient with clinical suspicion of PE.[164,165]	I	A
If CUS shows only a distal DVT, further testing should be considered to confirm PE.[177]	IIa	B
If a positive proximal CUS is used to confirm PE, assessment of PE severity should be considered to permit risk-adjusted management.[178,179]	IIa	C

2019 ESC Guidelines for the diagnosis and management of acute pulmonary embolism developed in collaboration with the European Respiratory Society (ERS)

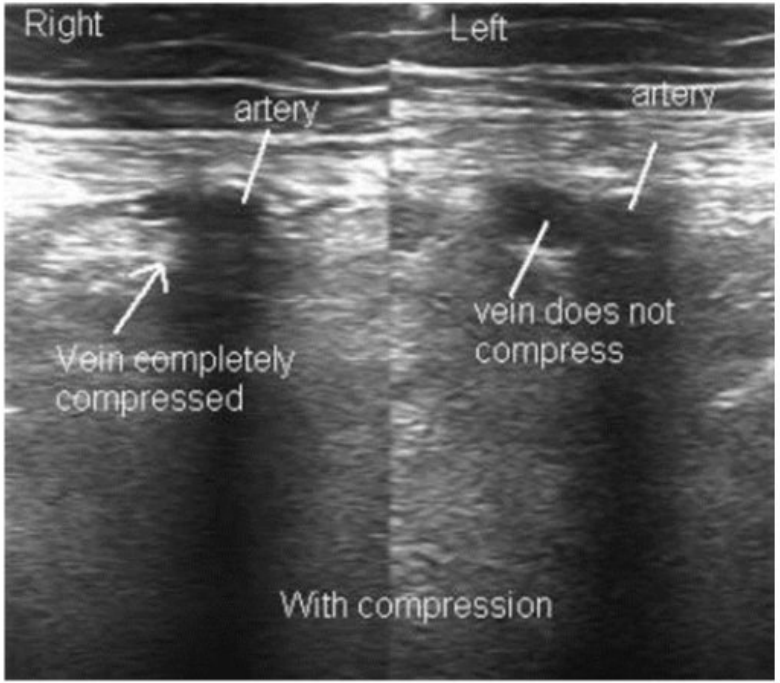
Right
Left
artery
artery
Vein completely compressed
vein does not compress
With compression