

7 key points for bifurcations

UOC Interventistica Cardiologica
e Diagnostica Invasiva



Francesco Burzotta
UOC Interventistica Cardiologica e
Diagnostica Invasiva

Gemelli

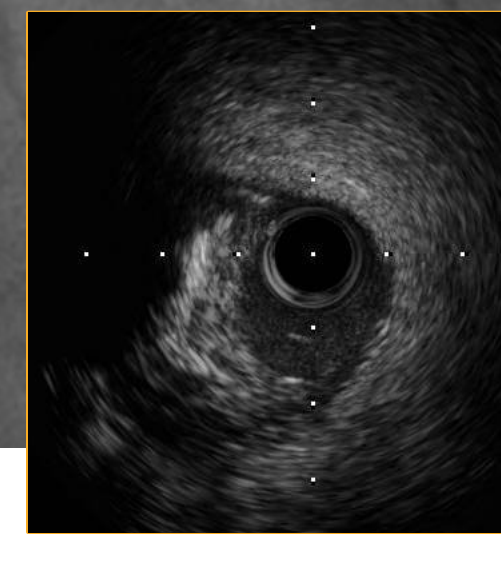
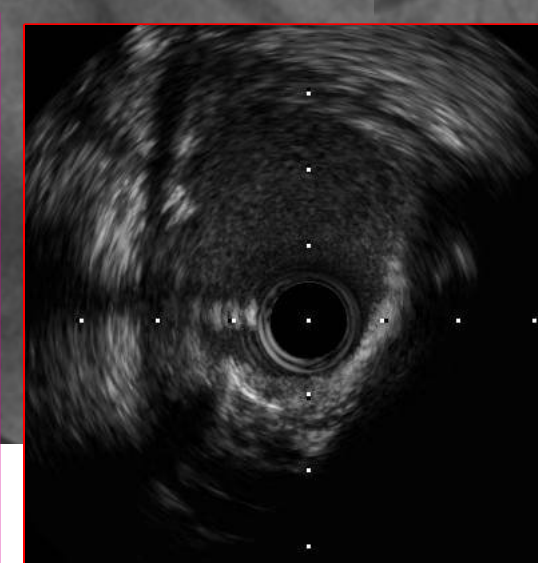
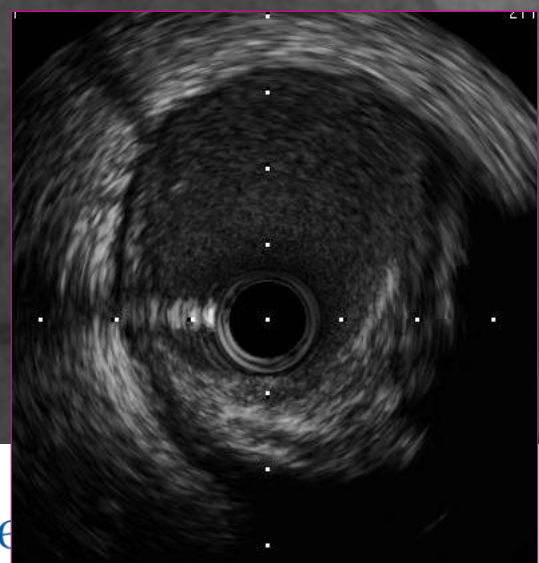
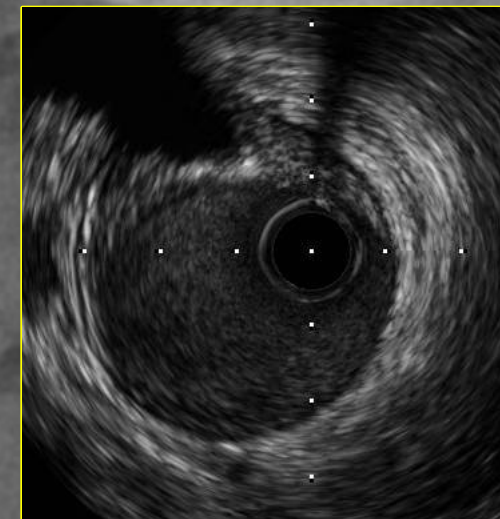
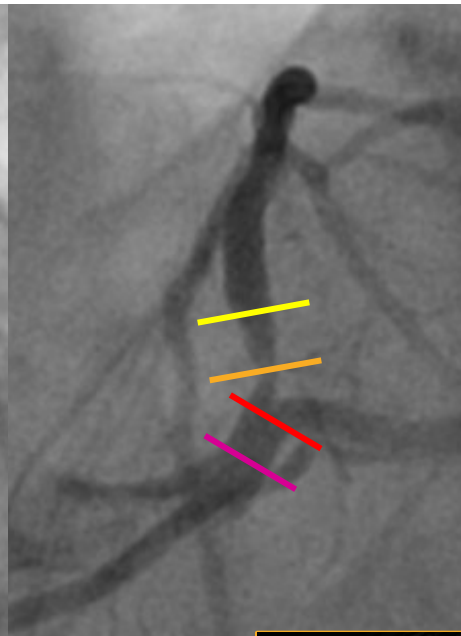
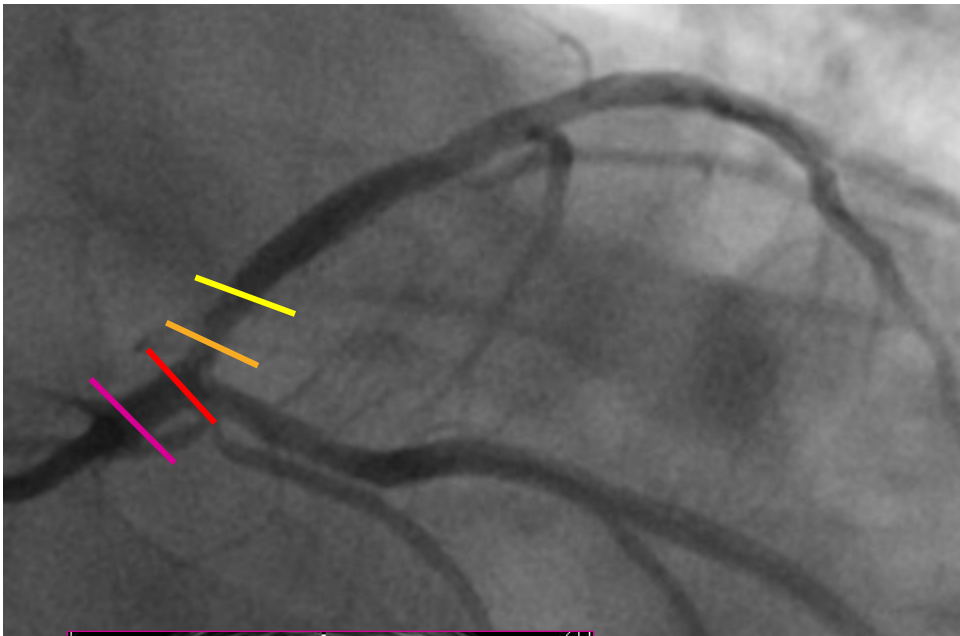


Fondazione Policlinico Universitario Agostino Gemelli IRCCS
Università Cattolica del Sacro Cuore

CONOSCI BENE IL TUO NEMICO





CONOSCI BENE IL TUO NEMICO



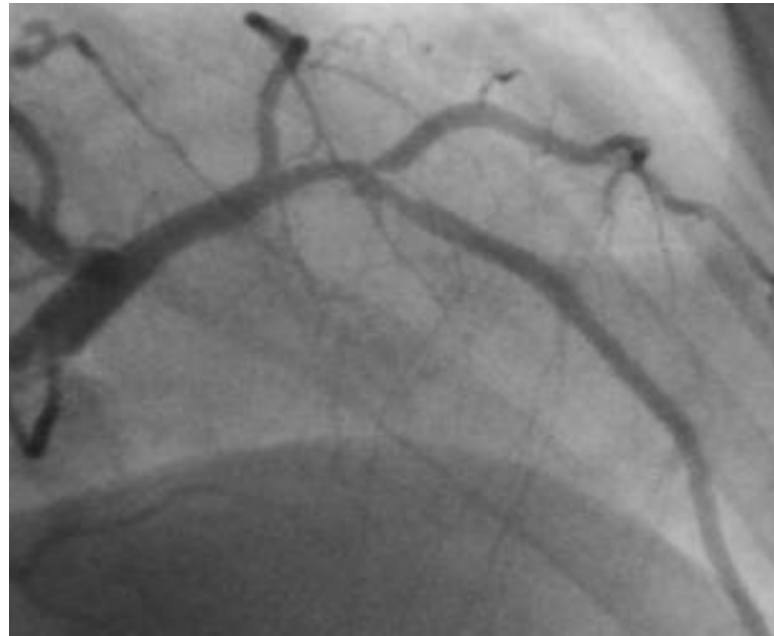


CONOSCI BENE IL TUO NEMICO

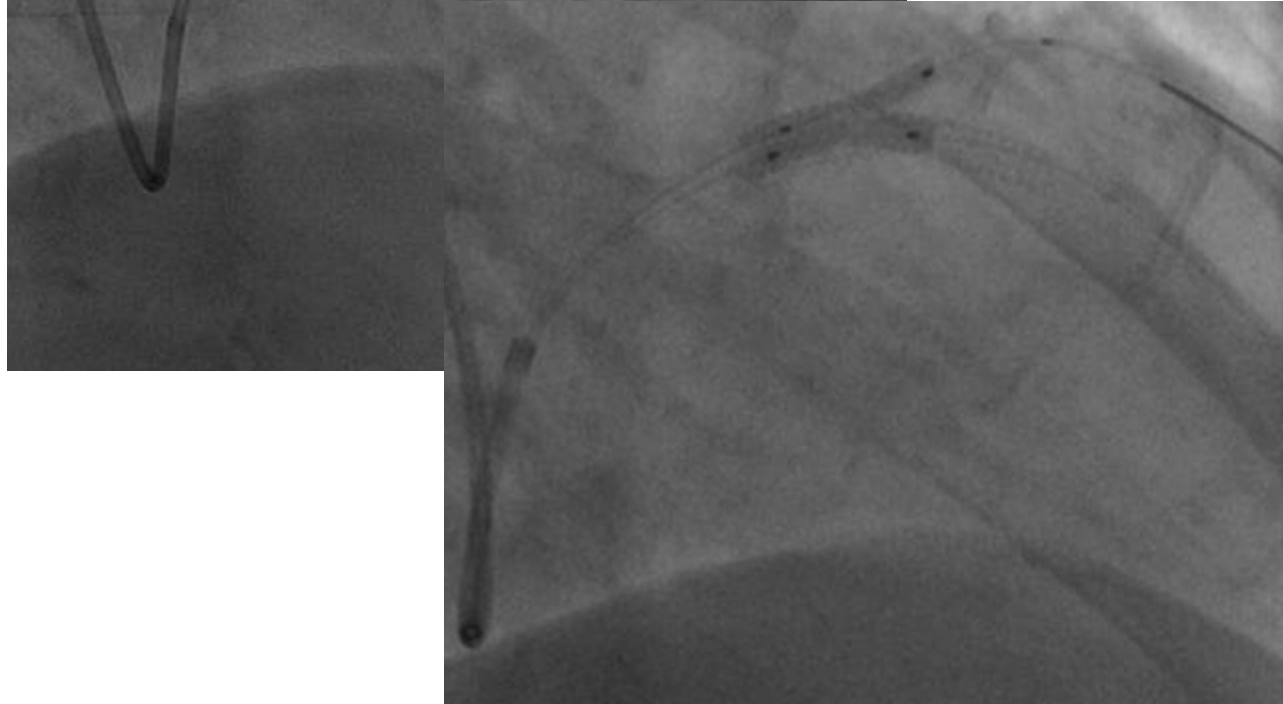
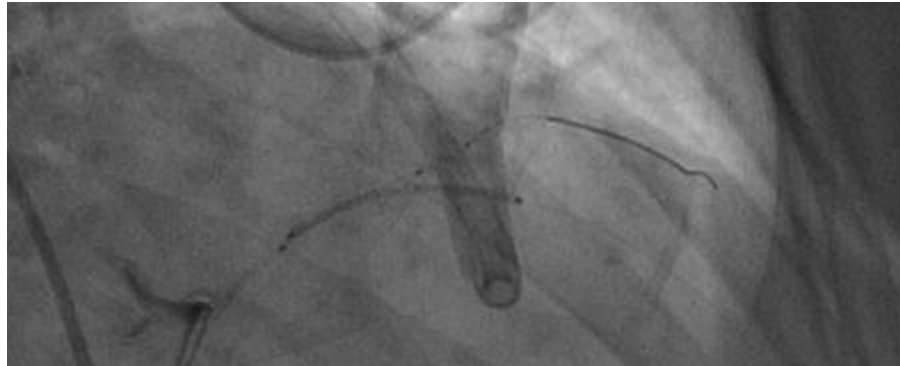
SB INVOLVED




SB NOT INVOLVED



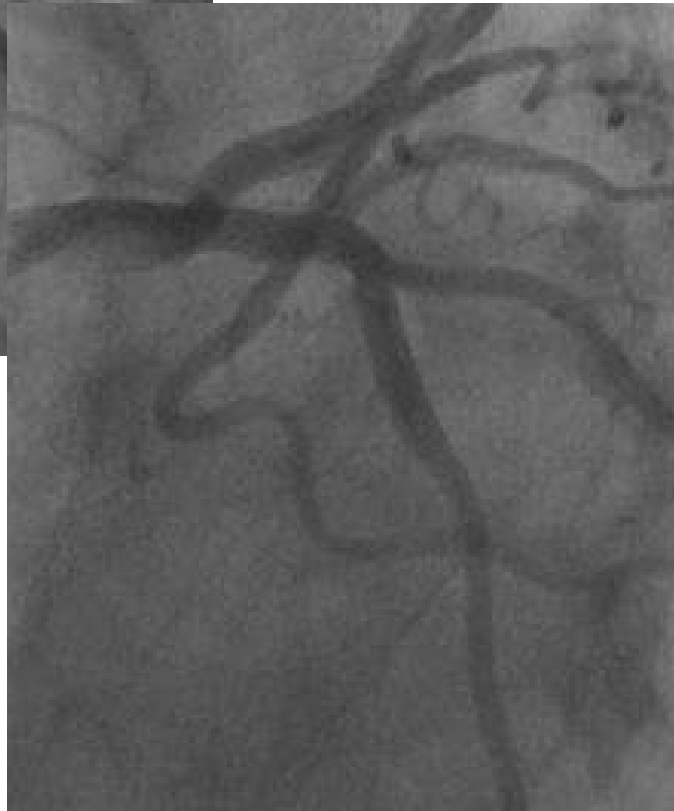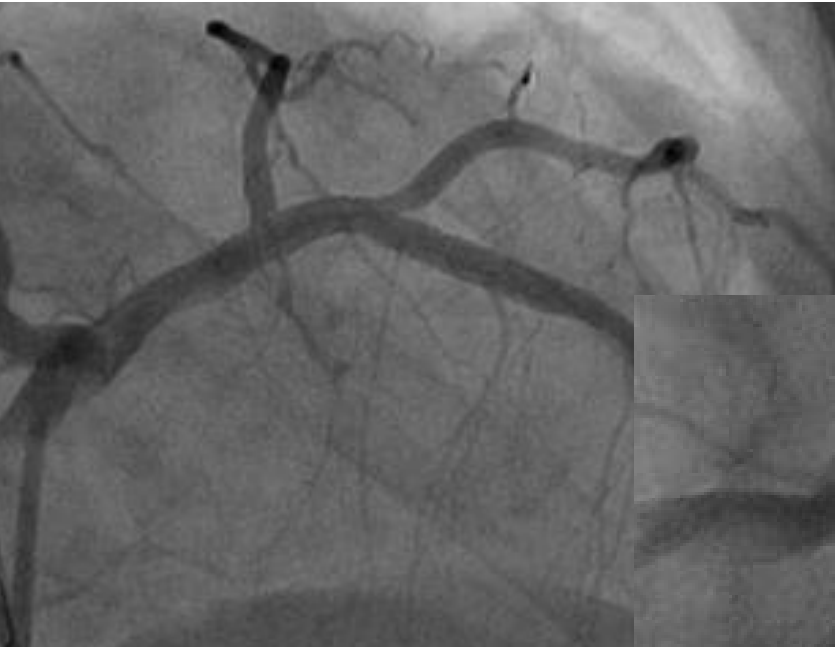CONOSCI BENE IL TUO NEMICO




SB NOT INVOLVED



CONOSCI BENE IL TUO NEMICO



SB NOT INVOLVED

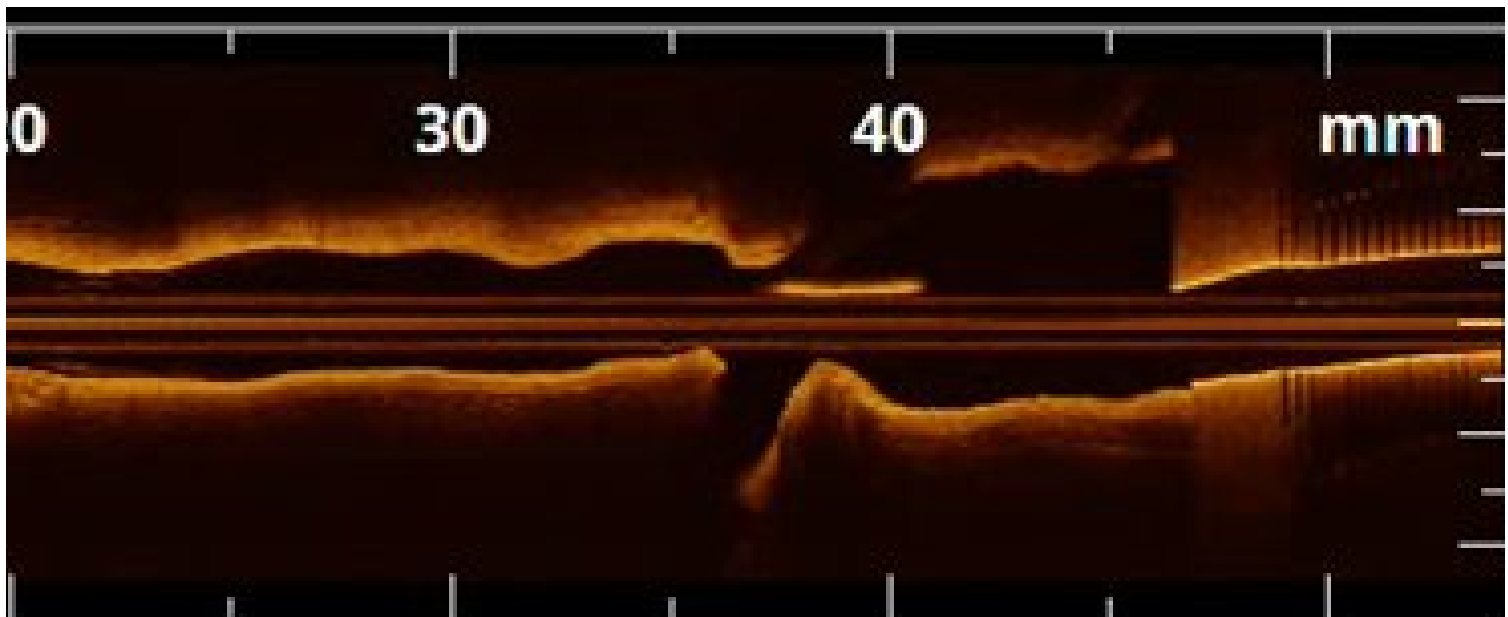


CONOSCI BENE IL TUO NEMICO




Frequency-domain optical coherence tomography findings in patients with bifurcated lesions undergoing provisional stenting

Francesco Burzotta*, Giovanni Paolo Talarico, Carlo Trani, Giovanni Luigi De Maria, Giancarlo Pirozzolo, Giampaolo Niccoli, Antonio Maria Leone, Silvia Saffioti, Italo Porto, and Filippo Crea



PIANFICA BENE LA TUA STRATEGIA

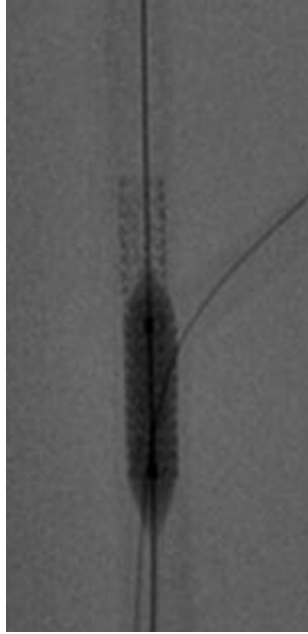
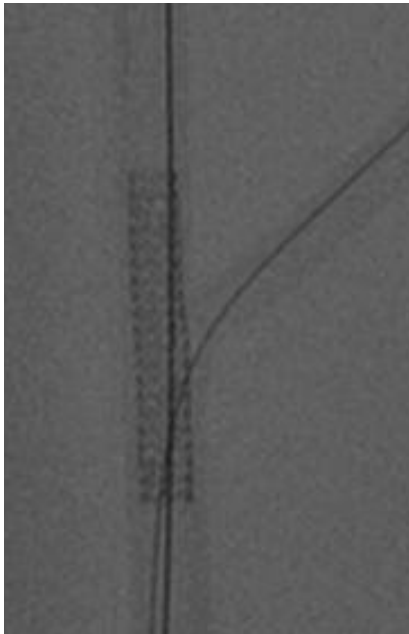


PIANIFICA BENE LA TUA STRATEGIA

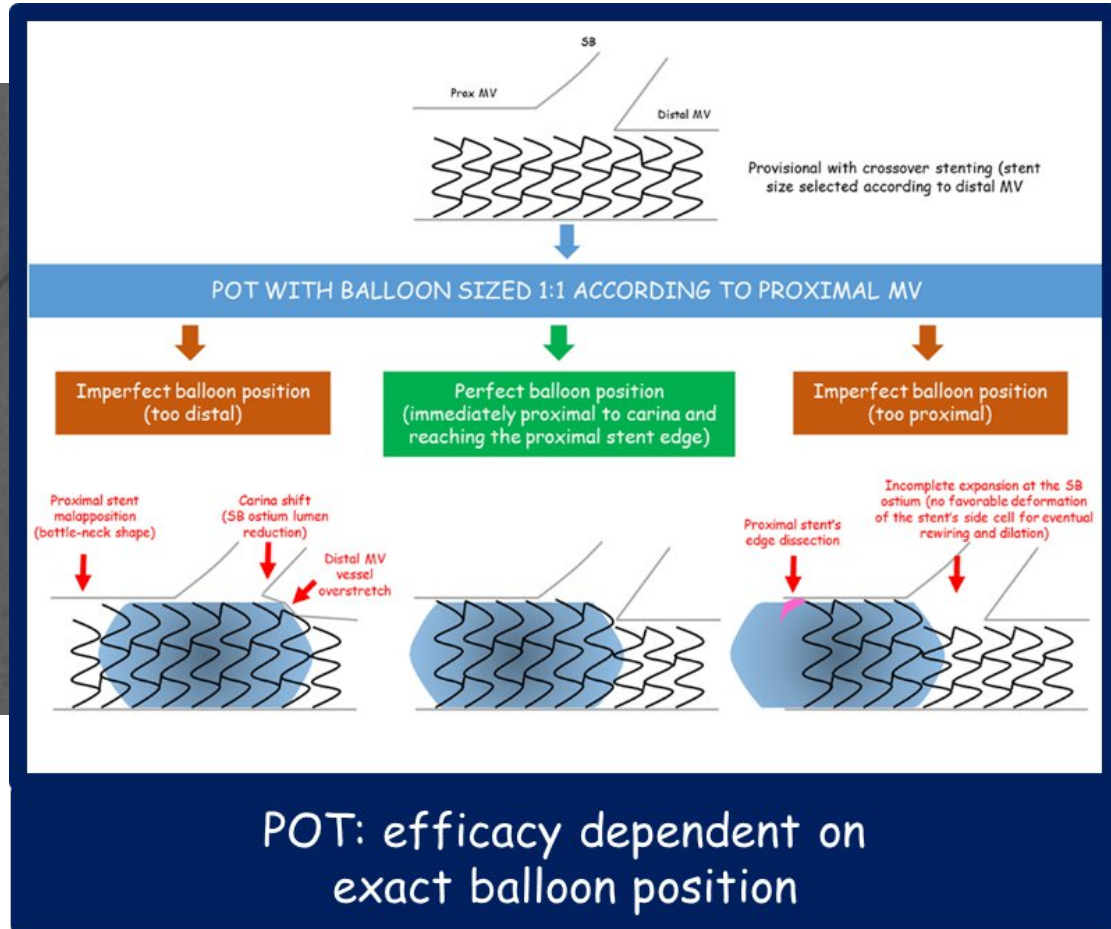


	M Main prox. first	A Main Across side first (Provisional)	D Double prox. lumen	S Side branch first	Inverted	Inverted A Across distal main first (Inverted Provisional)	DM Distal Main first
1st stent	 PM stenting	 MB cross-over stenting		 SB ostial stenting	 1 st stent	 MB to SB stenting	 DM ostial stenting
Ballooning	 Skirt (K)	 POT Side-branch dilation Kissing		 Balloon SB crush	 POT Kissing	 Balloon DM crush	
2nd, 3rd stent, (and further ballooning)	 Extended skirt (K)	 T TAP Culotte	 V / SKS	 Intentional T stenting Step/DK crush	 2 nd stent (and further ballooning)	 Inv. T Inv. TAP Inv. Culotte	 Inv. Intentional T stenting Inv. Step/DK crush
Dedicated Device	Axxess	Bioss LIM, Xposition Stentys, Nile SIR		Capella Side-Guard		Tryton	

PIANIFICA BENE LA TUA STRATEGIA

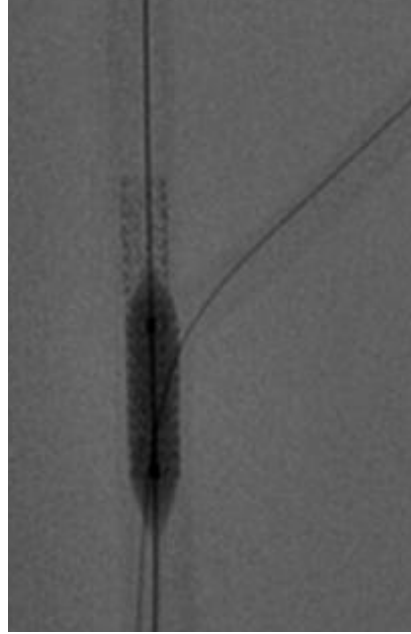
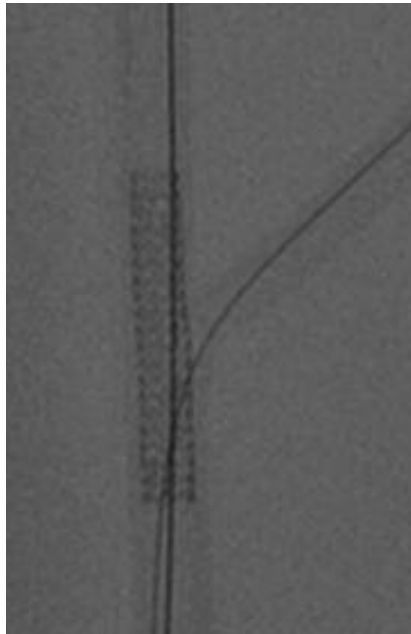


POT

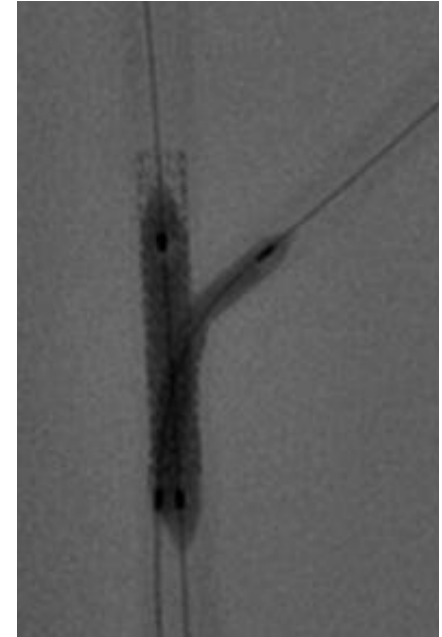
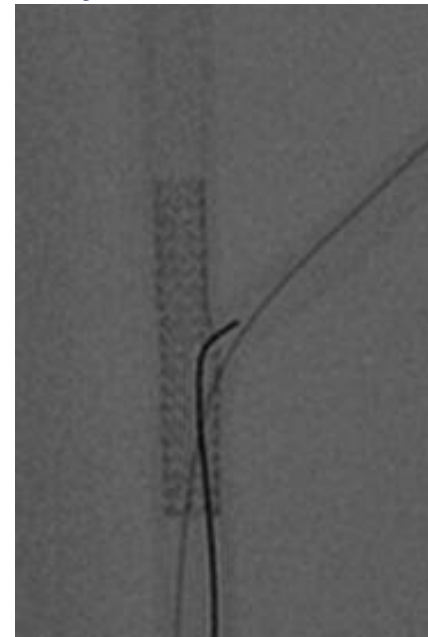


CROSSOVER
STENTING
WITH STENT SIZING
ACCORDING TO
DISTAL MV

PIANIFICA BENE LA TUA STRATEGIA



In the case of need
for SB intervention



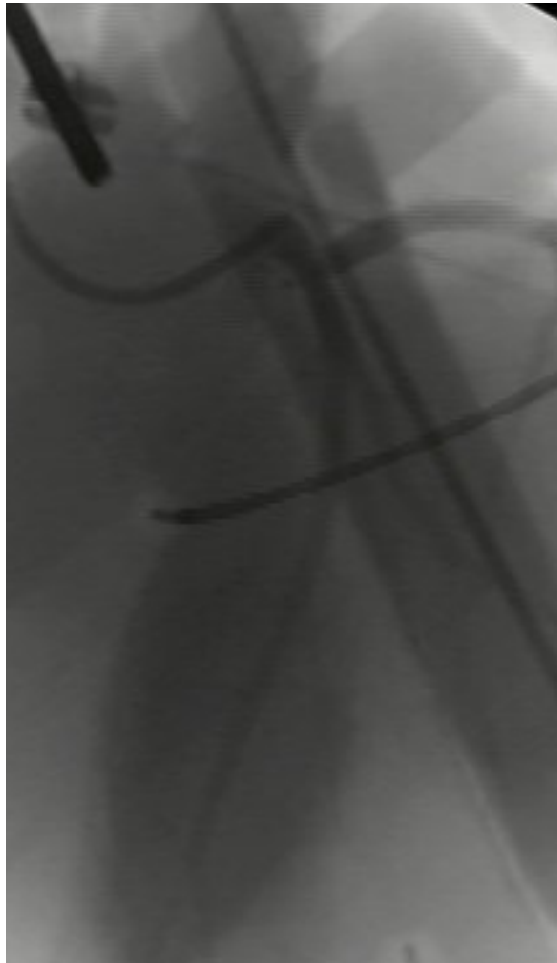**CROSSOVER
STENTING
WITH STENT SIZING
ACCORDING TO
DISTAL MV**

POT

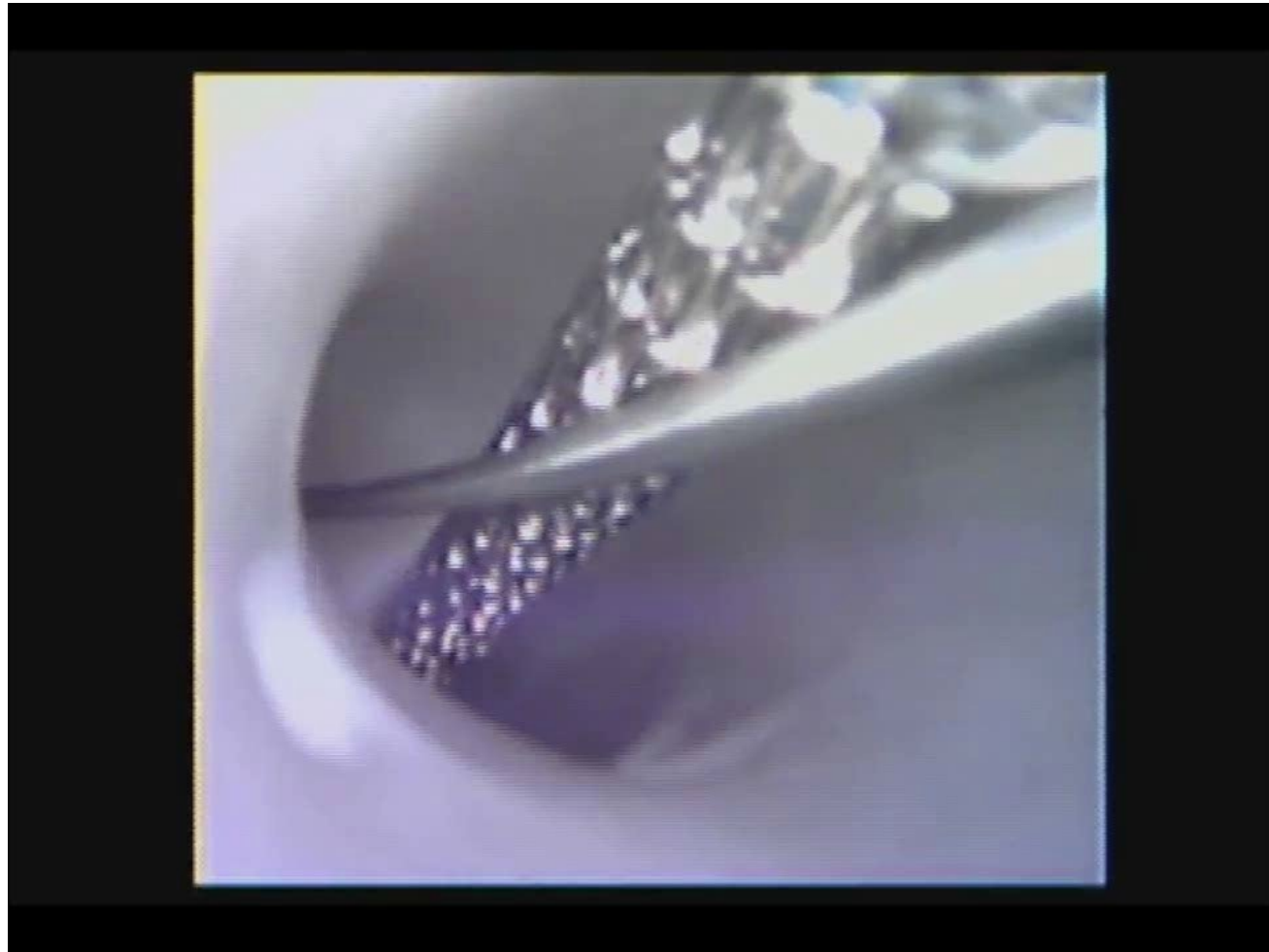
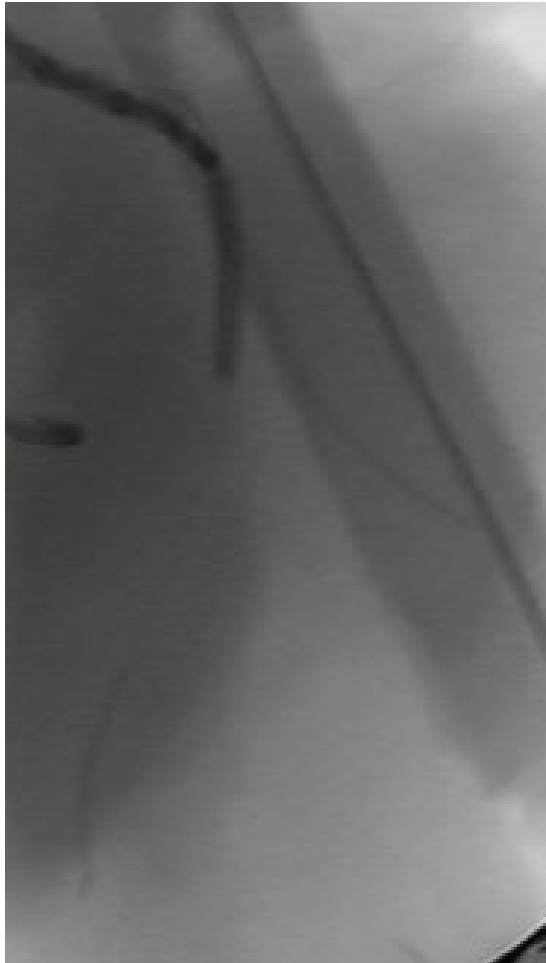
**DISTAL
REWIRING**

KISSING



PIANIFICA BENE LA TUA STRATEGIA



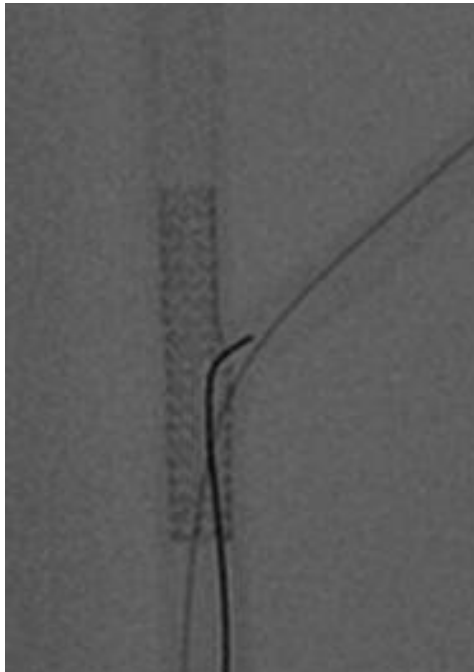
PIANIFICA BENE LA TUA STRATEGIA



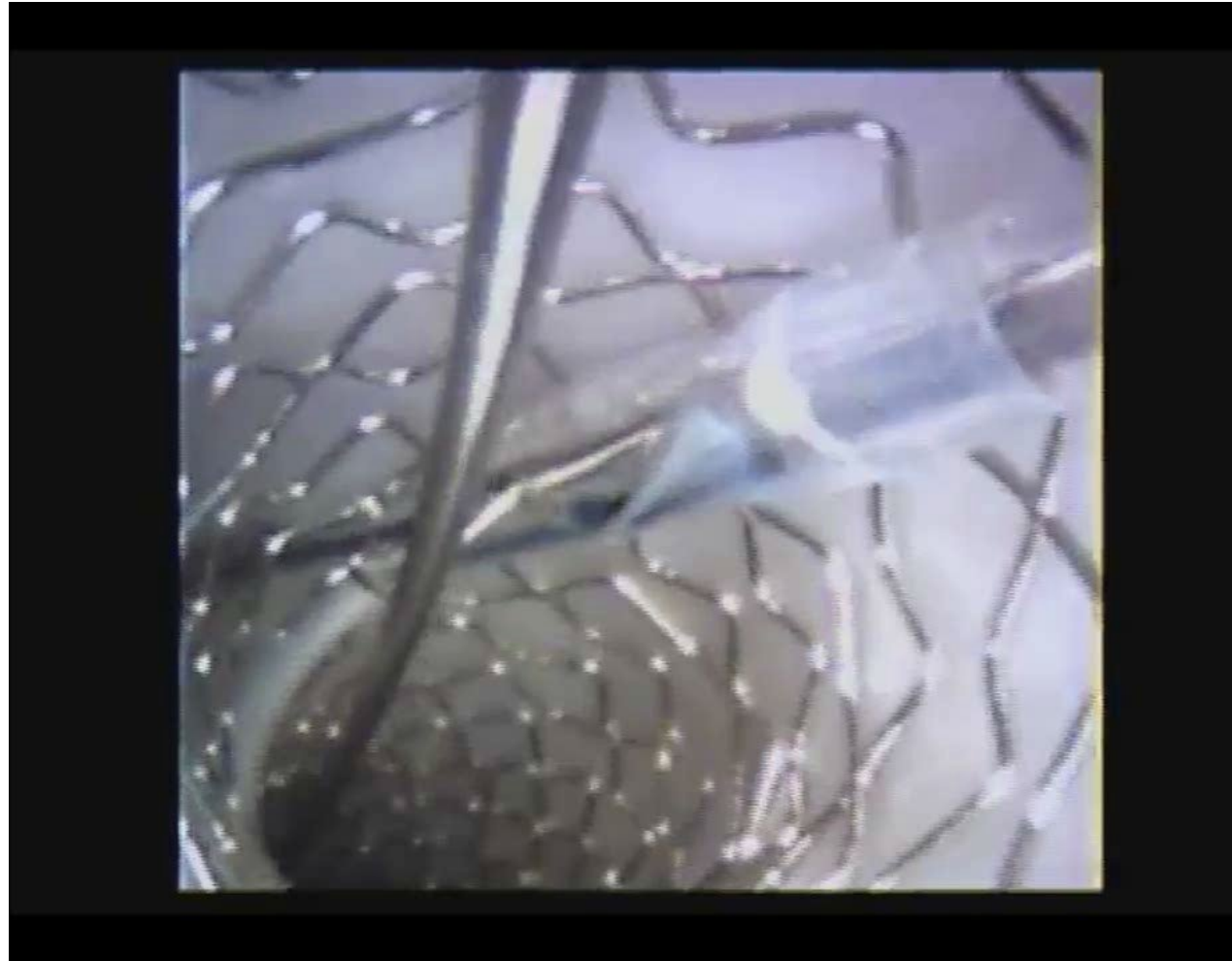
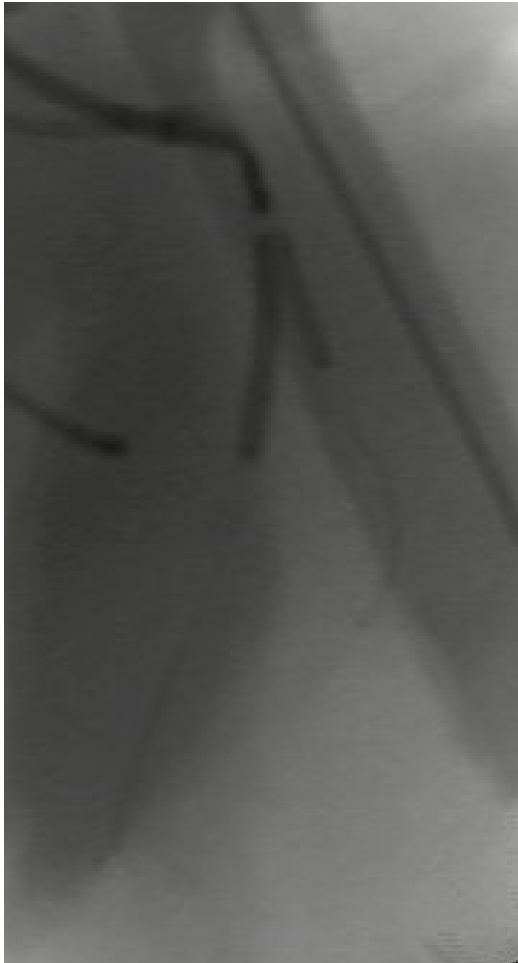PIANIFICA BENE LA TUA STRATEGIA



PIANIFICA BENE LA TUA STRATEGIA



PIANIFICA BENE LA TUA STRATEGIA



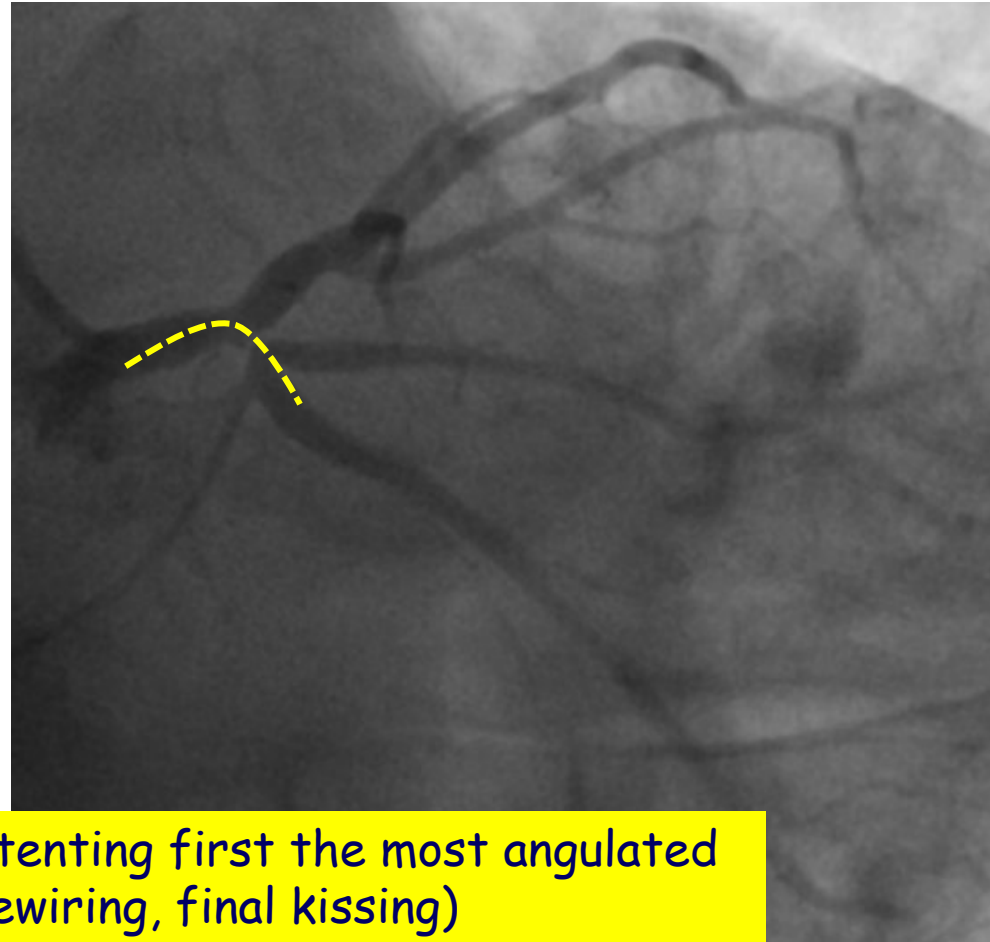
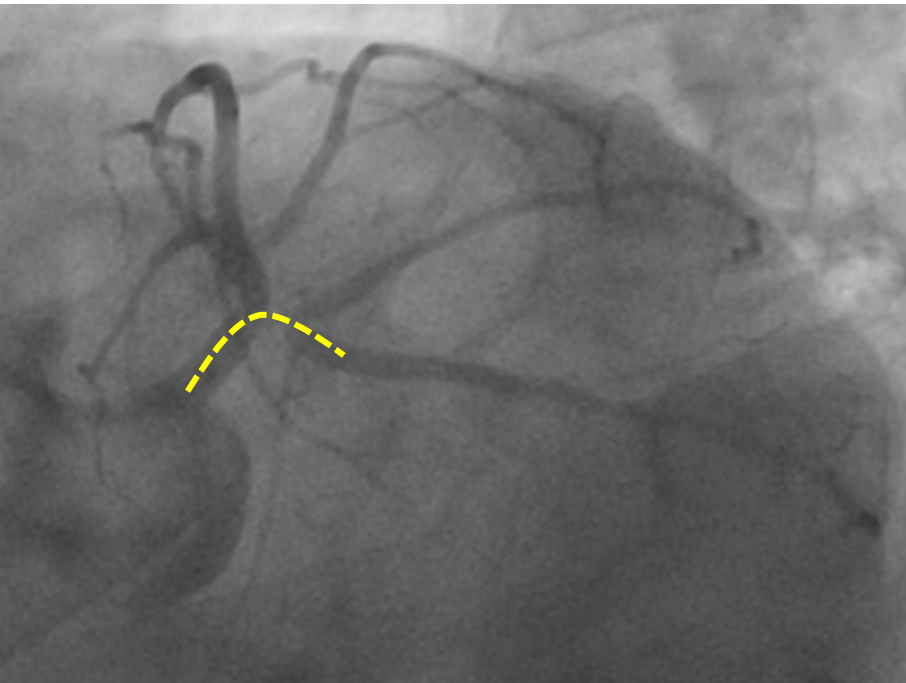

PIANIFICA BENE LA TUA STRATEGIA



SELEZIONA CON ATTENZIONE IL TUO PRIMO BERSAGLIO



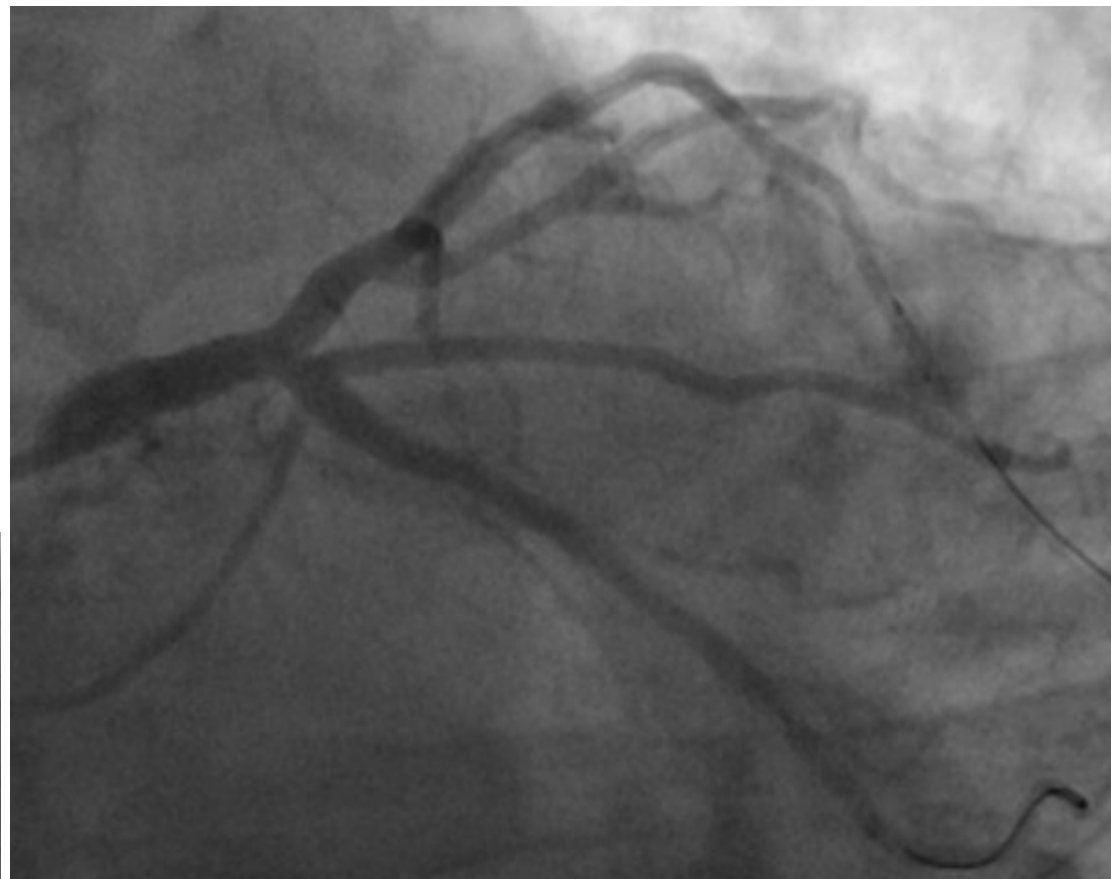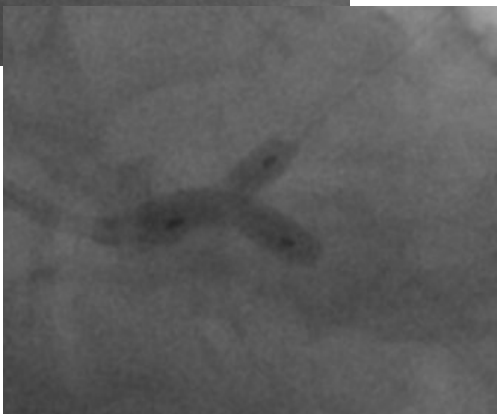
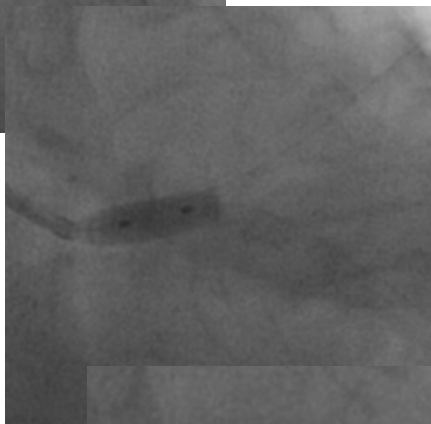
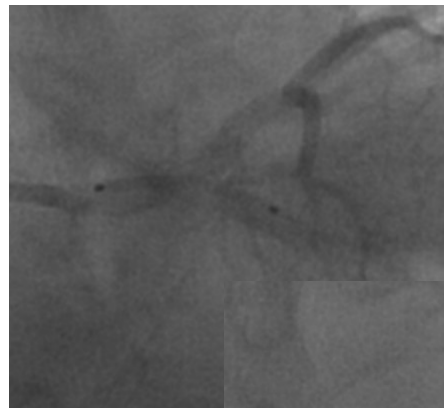SELEZIONA CON ATTENZIONE IL TUO PRIMO BERSAGLIO ...in single stent strategy



"INVERTED" PROVISIONAL (stenting first the most angulated branch, POT, distal rewiring, final kissing)

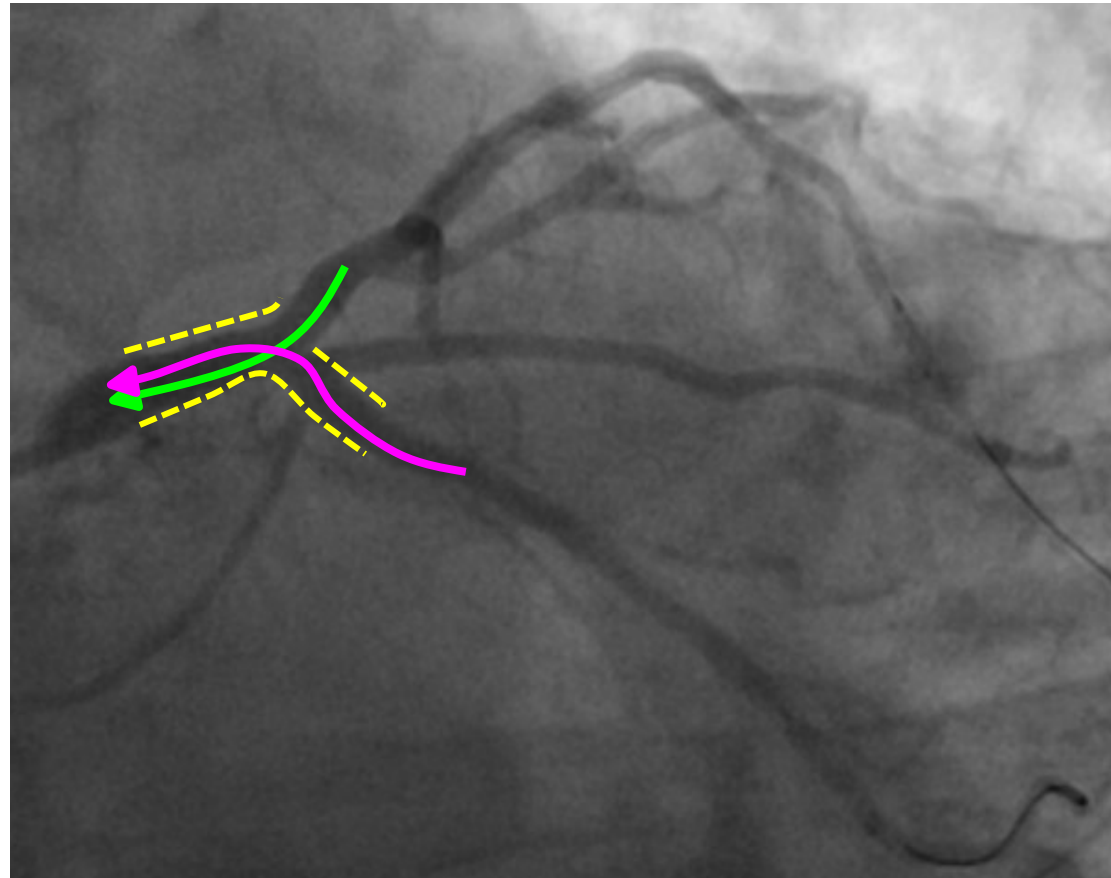
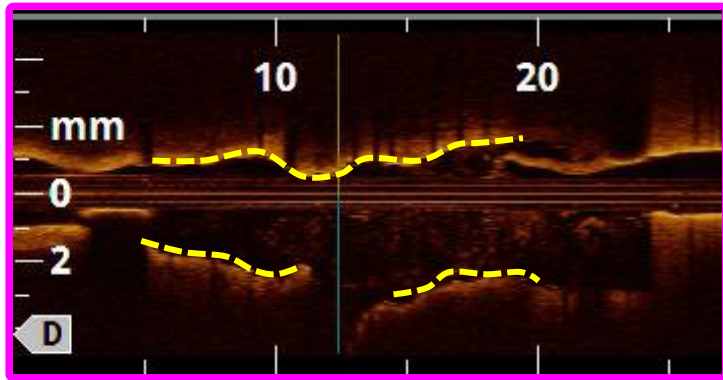
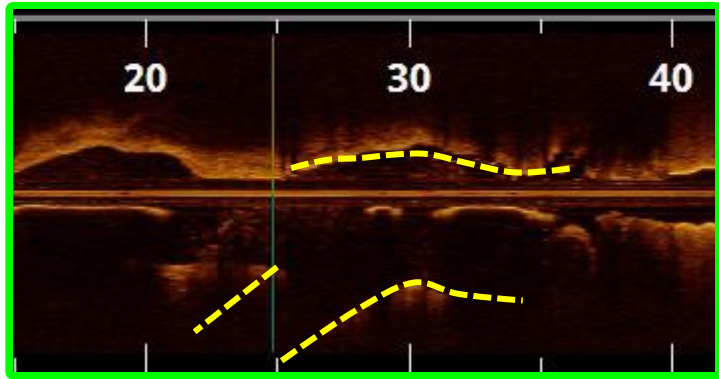
SELEZIONA CON ATTENZIONE IL TUO PRIMO BERSAGLIO

...in single stent strategy



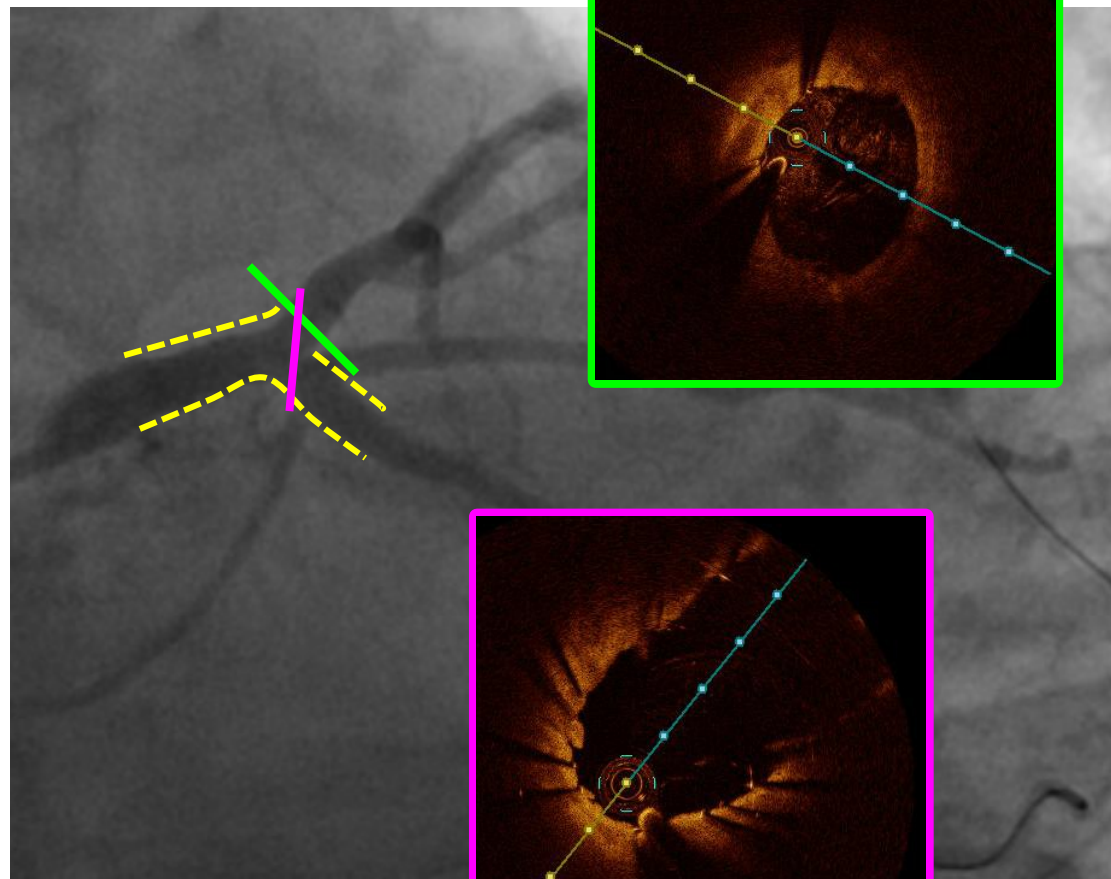
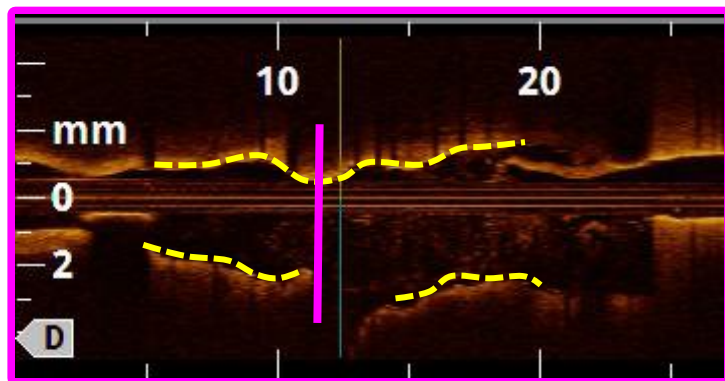
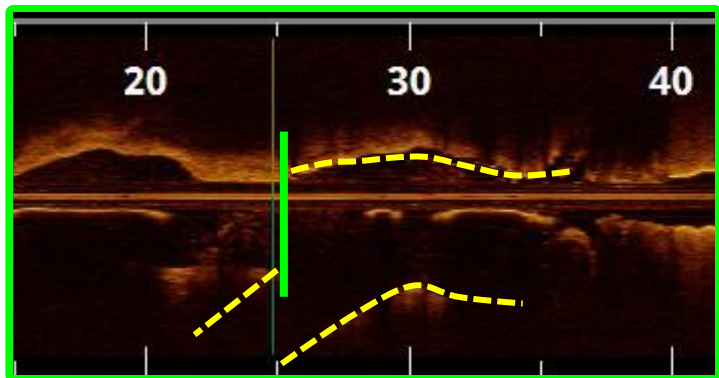
SELEZIONA CON ATTENZIONE IL TUO PRIMO BERSAGLIO

...in single stent strategy

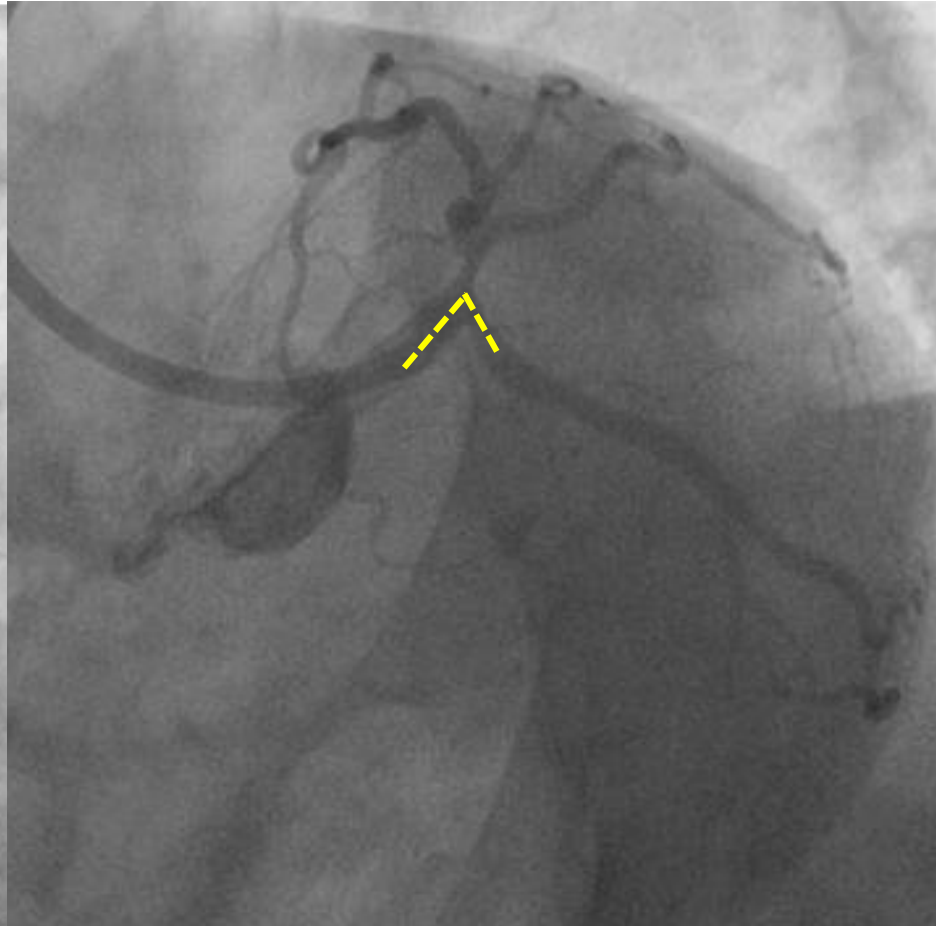
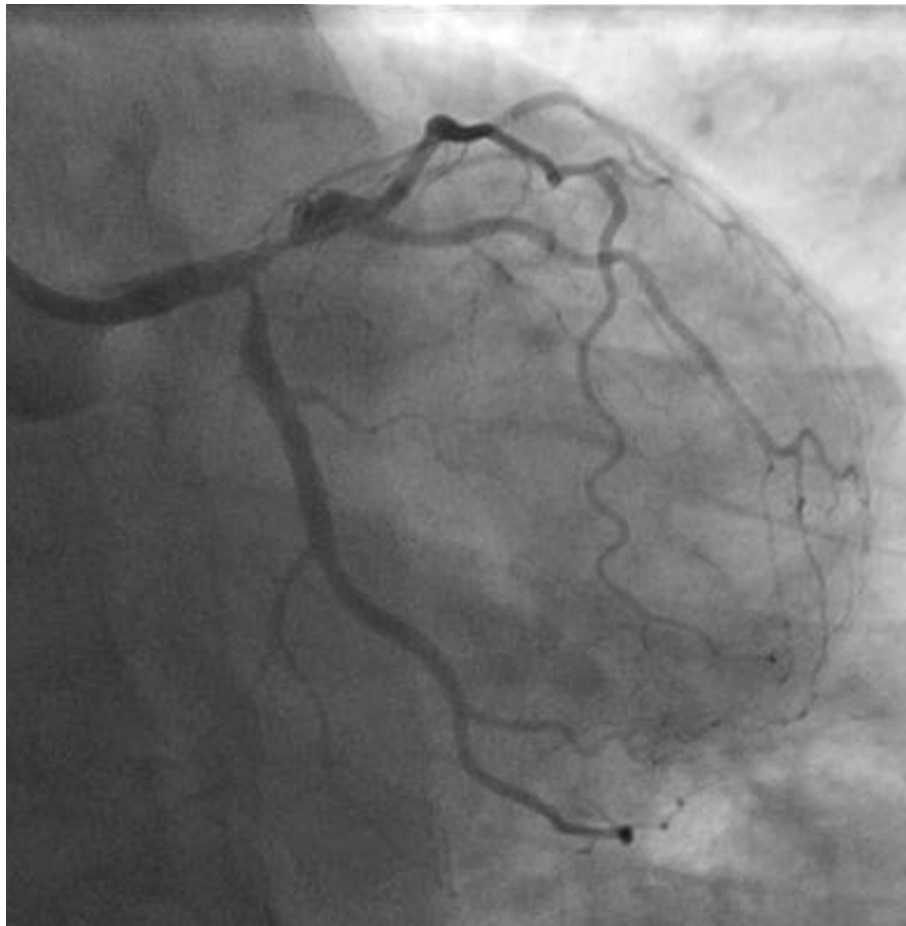


SELEZIONA CON ATTENZIONE IL TUO PRIMO BERSAGLIO

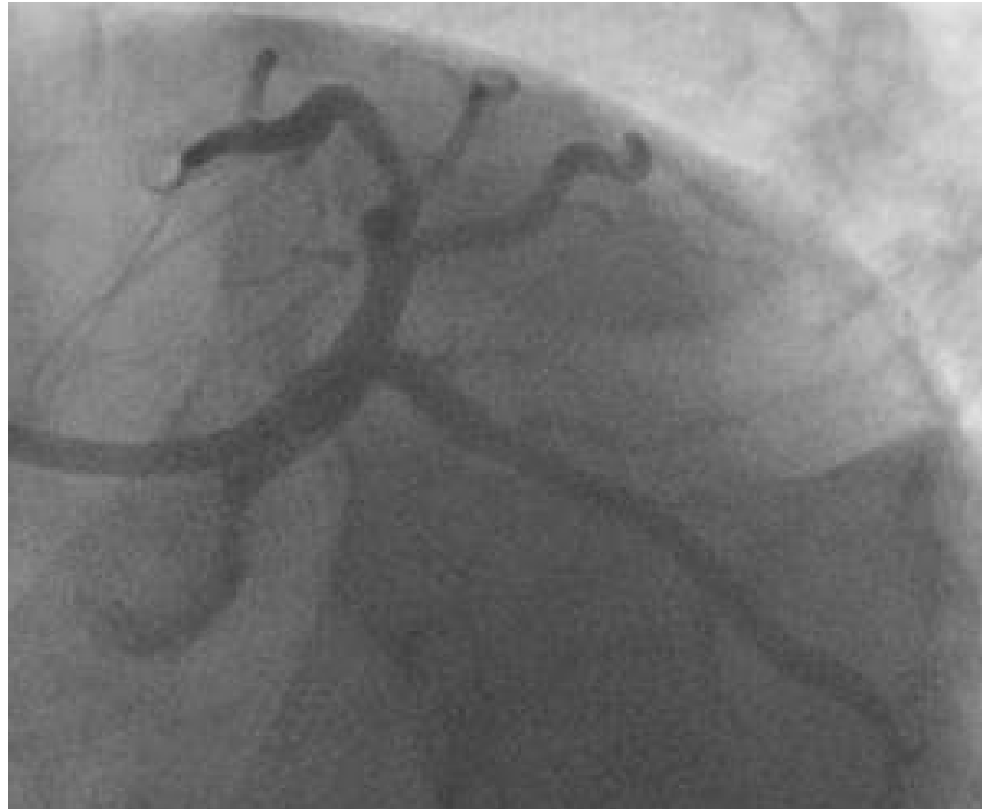...in single stent strategy



SELEZIONA CON ATTENZIONE IL TUO PRIMO BERSAGLIO ...in double stent strategy



SELEZIONA CON ATTENZIONE IL TUO PRIMO BERSAGLIO ...in double stent strategy



“INVERTED” TAP (stenting first the most angulated branch, POT, distal rewiring, kissing, TAP, final kissing)

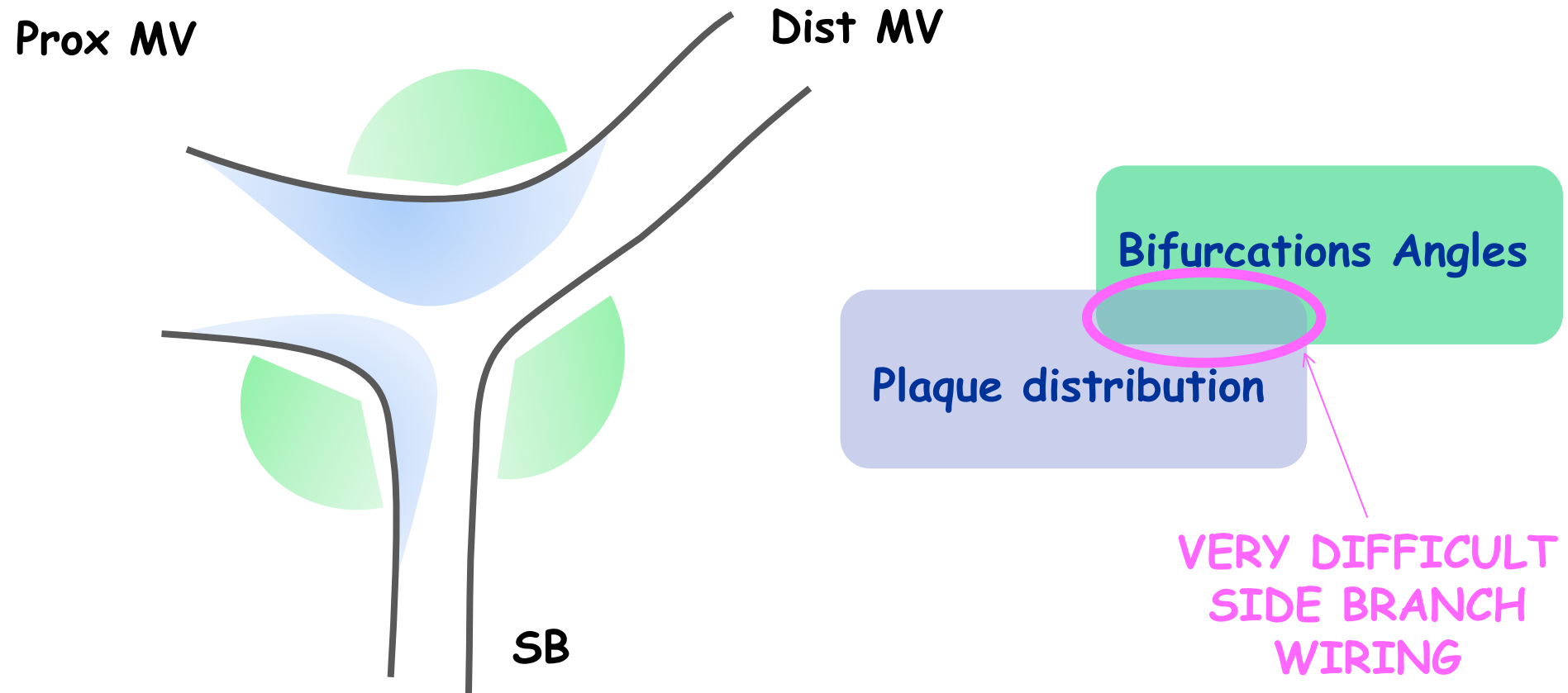
PREPARA LE TUE ARMI PER LA BATTAGLIA !!!



DIFFICULT WIRING



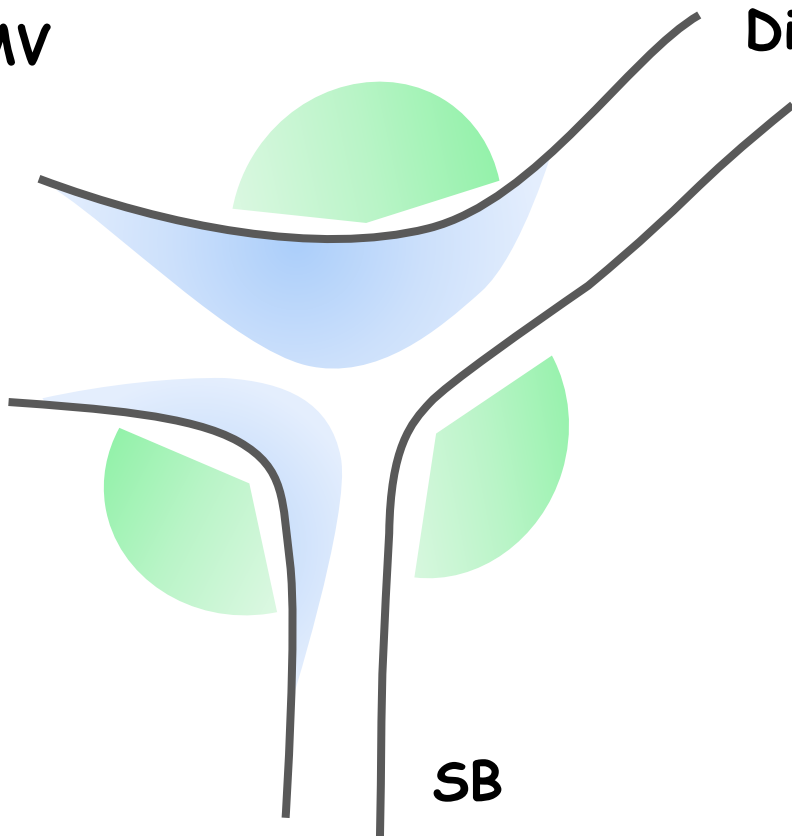
DIFFICULT WIRING

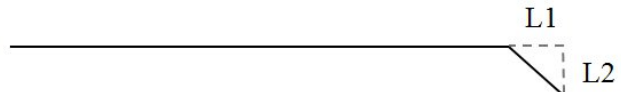





DIFFICULT WIRING

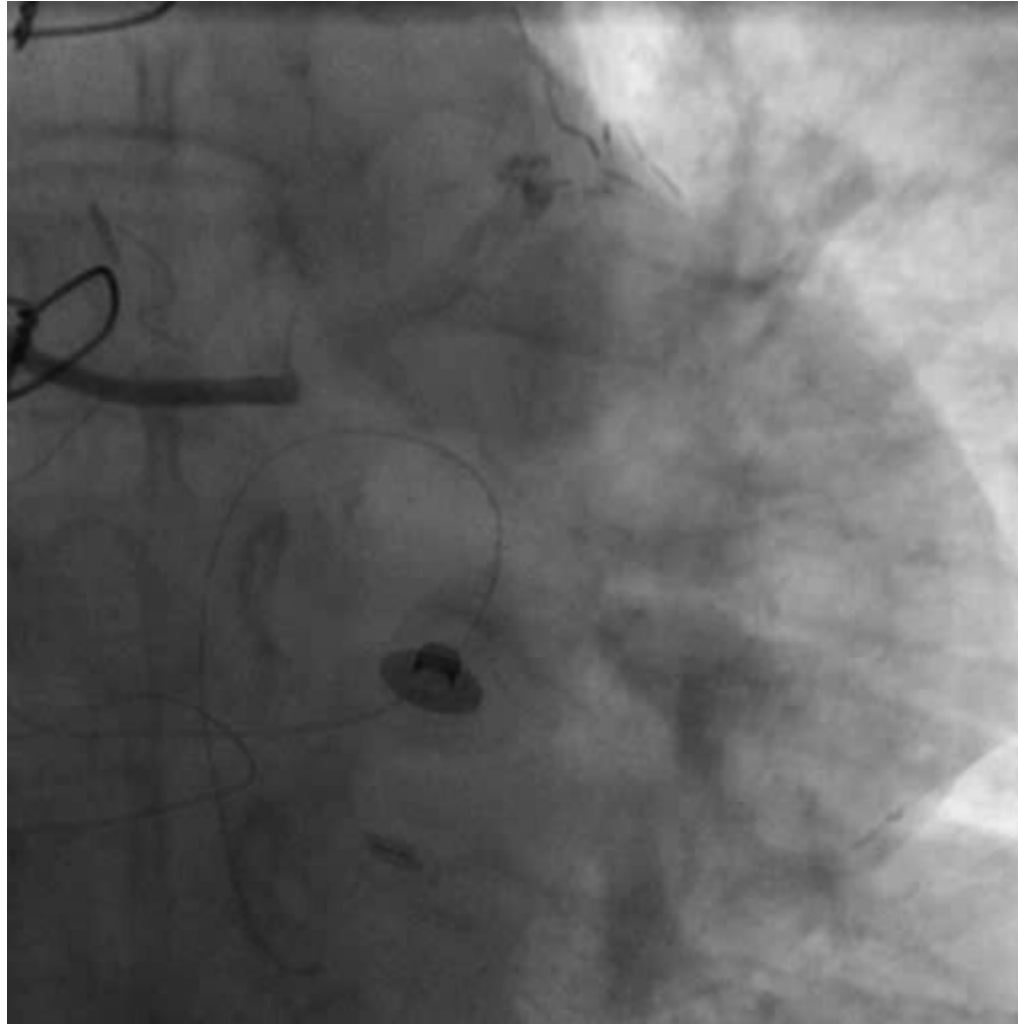
Prox MV

Dist MV

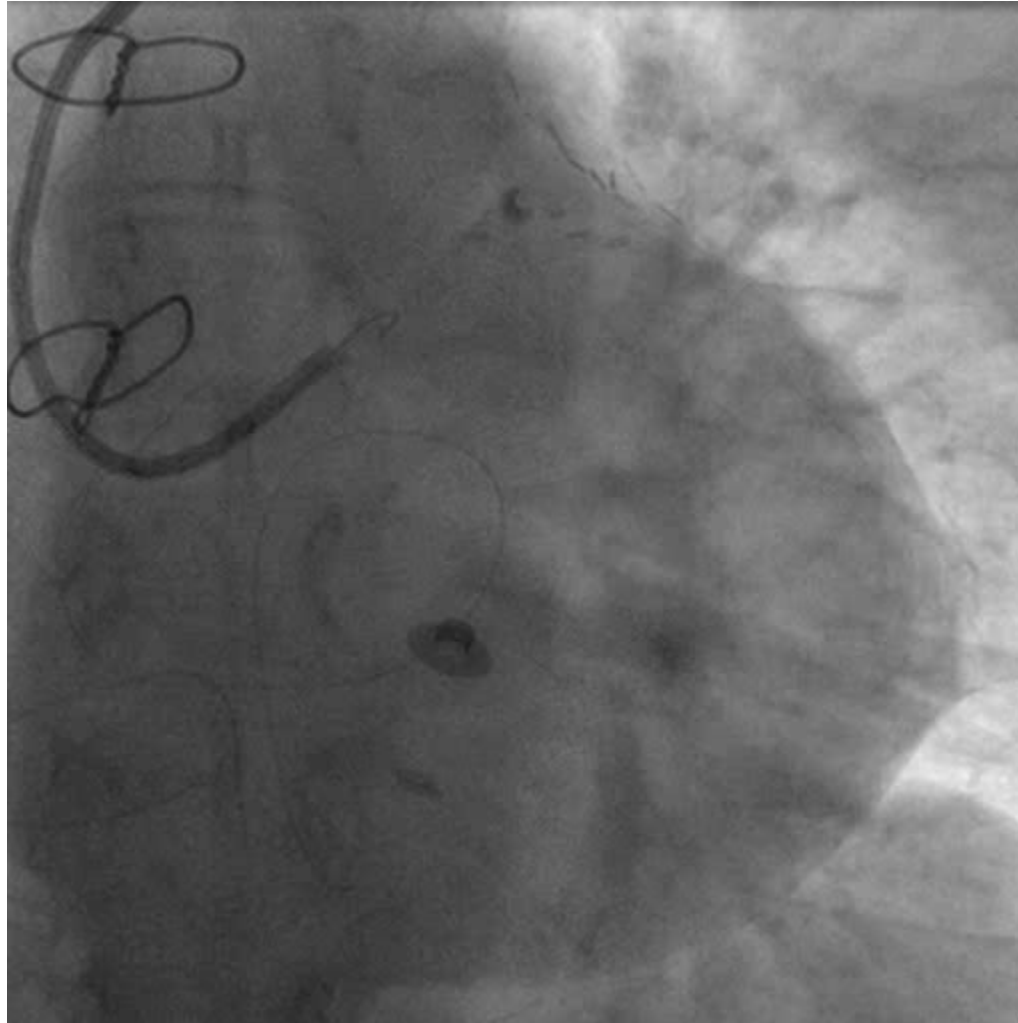


1. single bend, short tip 
2. single bend, long tip 
3. wide smooth bend 
4. double bend 

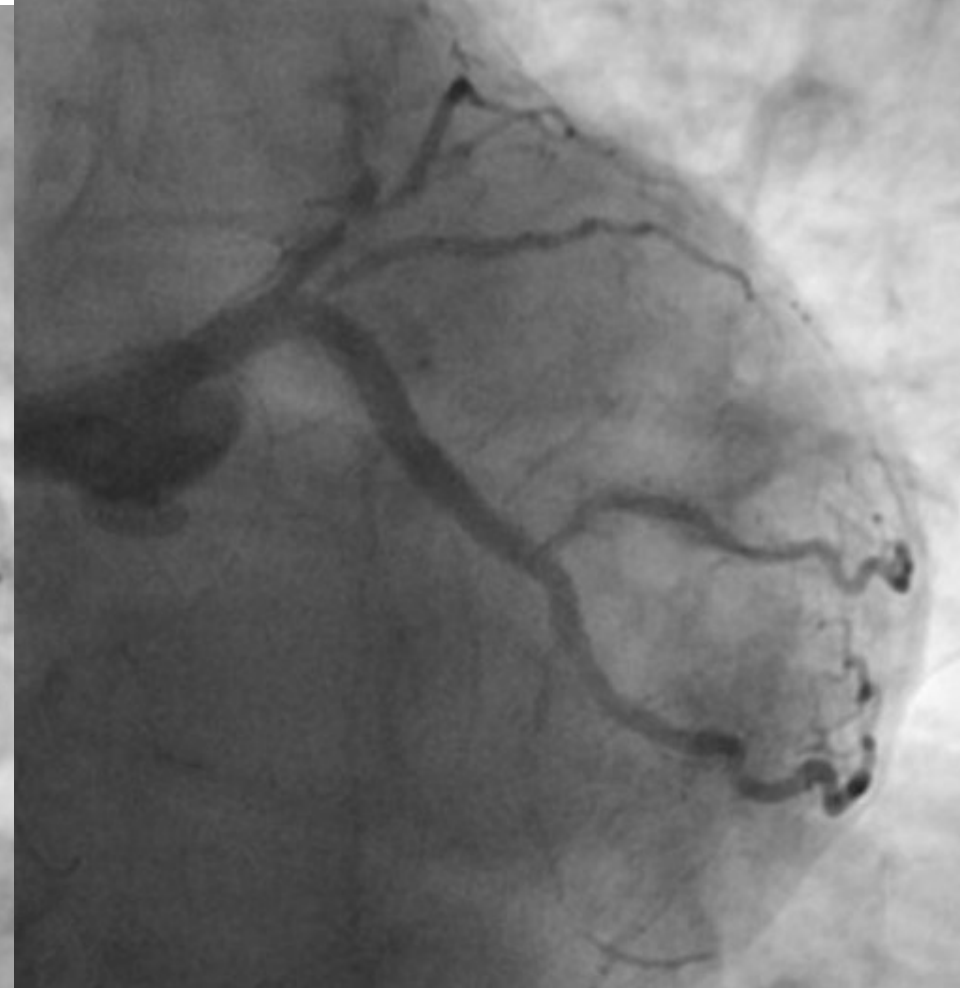
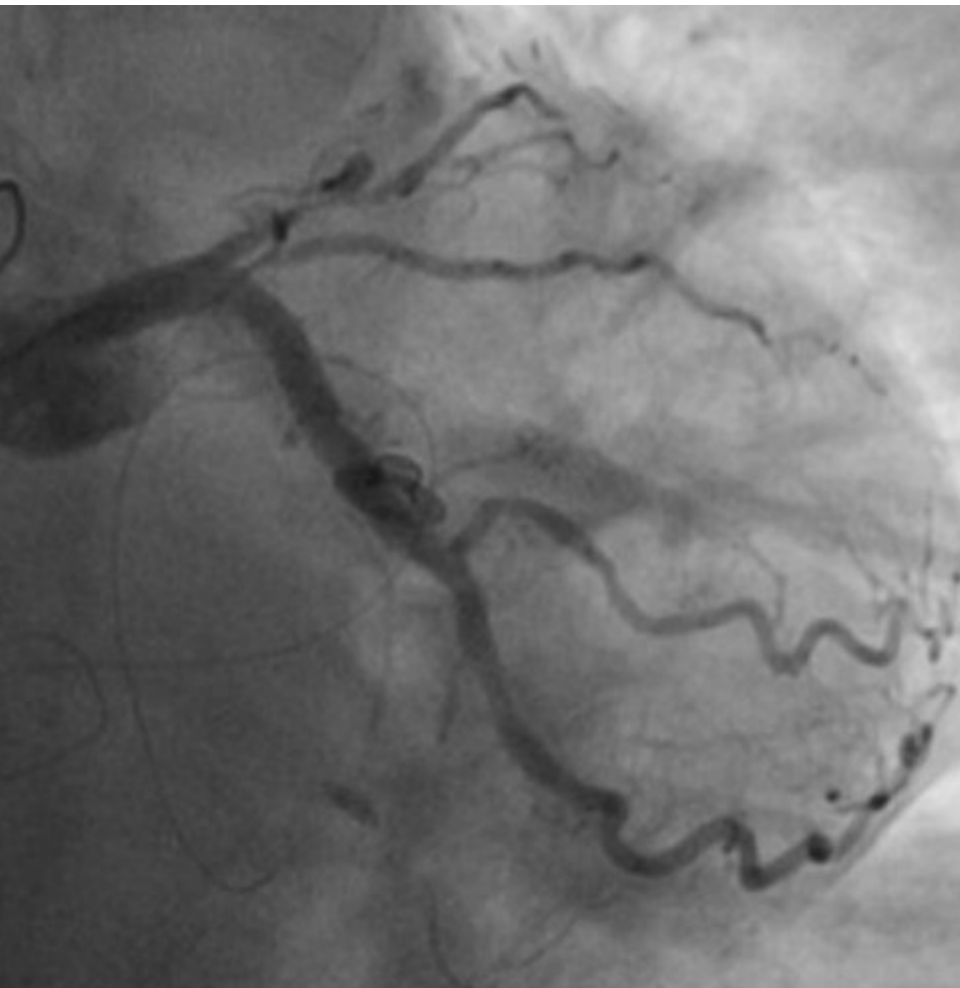
DIFFICULT WIRING



DIFFICULT WIRING



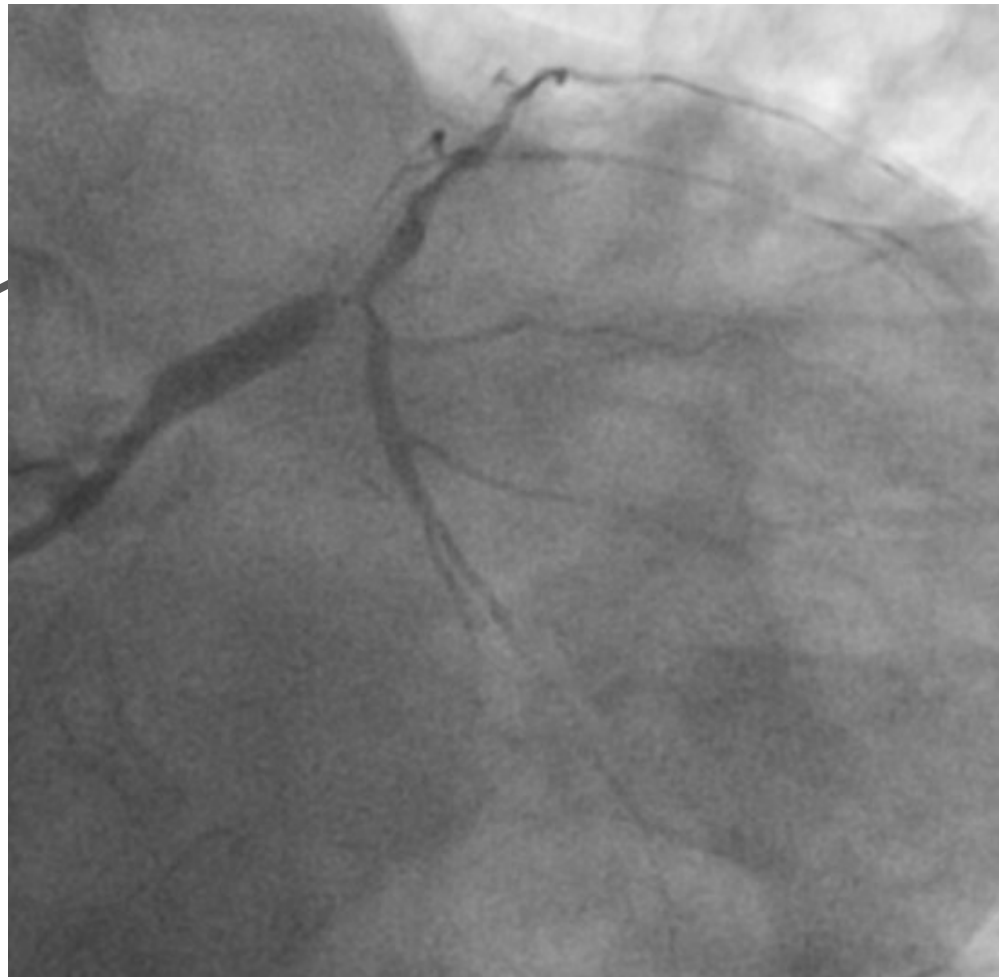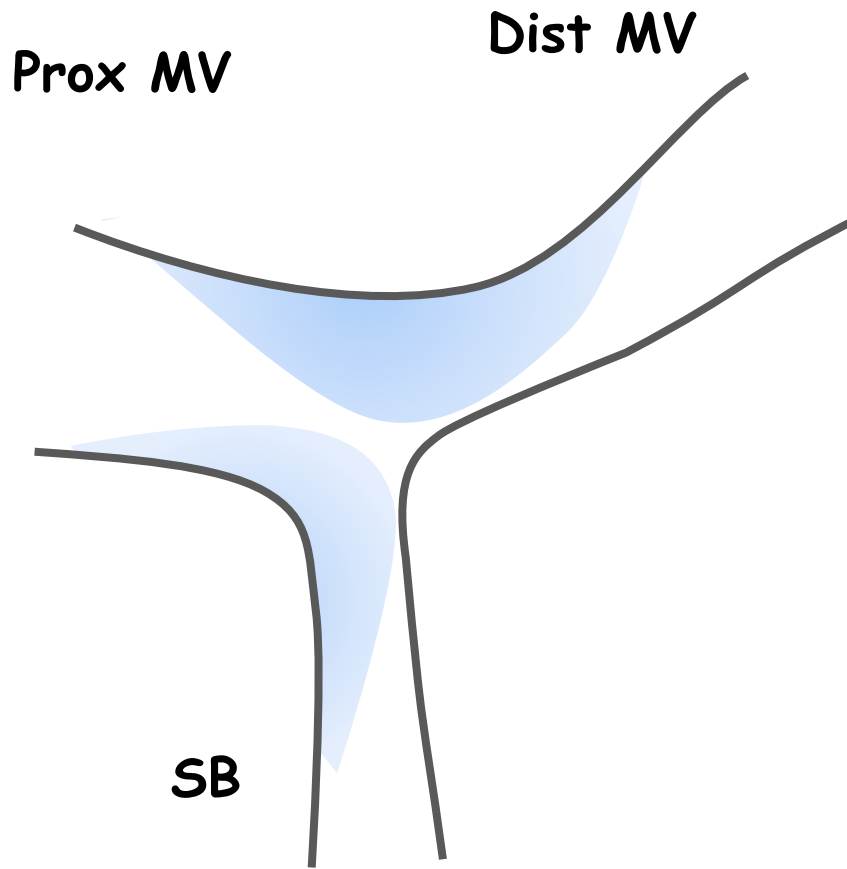
DIFFICULT WIRING



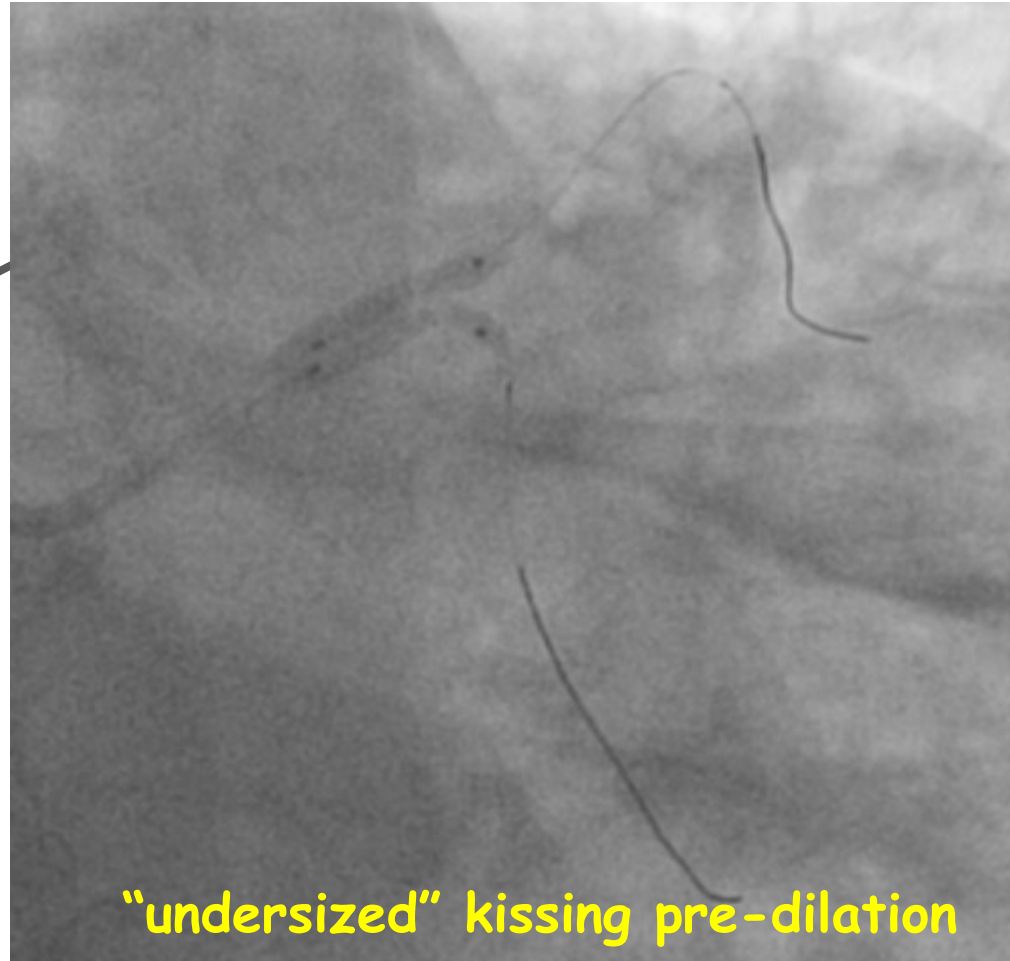
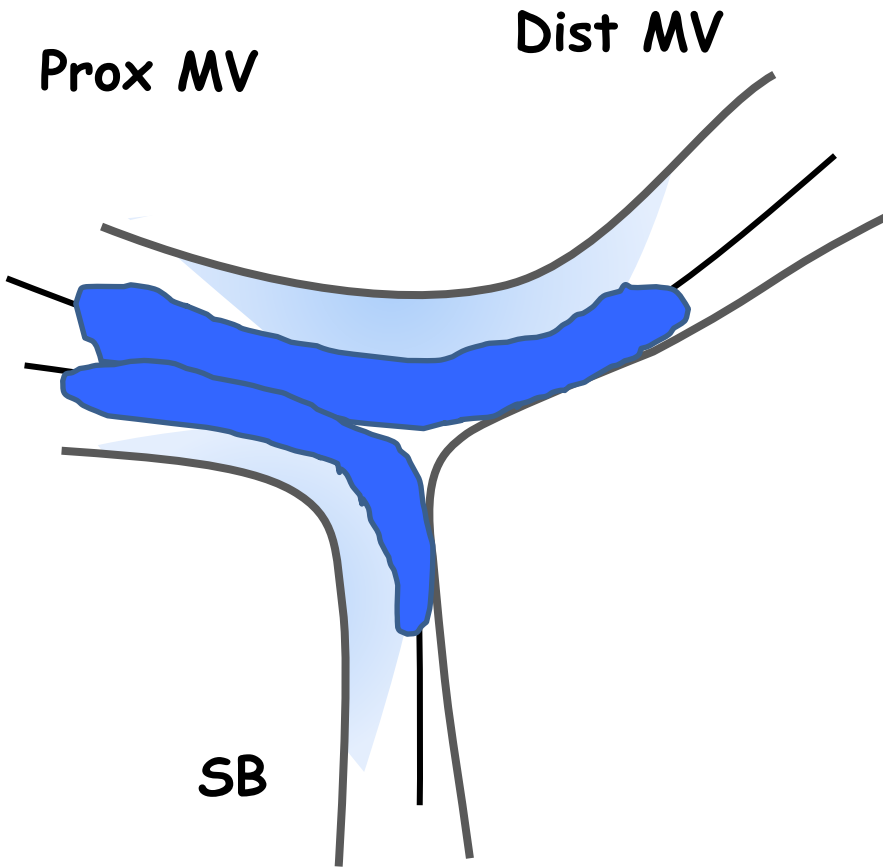
LIMITA I RISCHI !!!



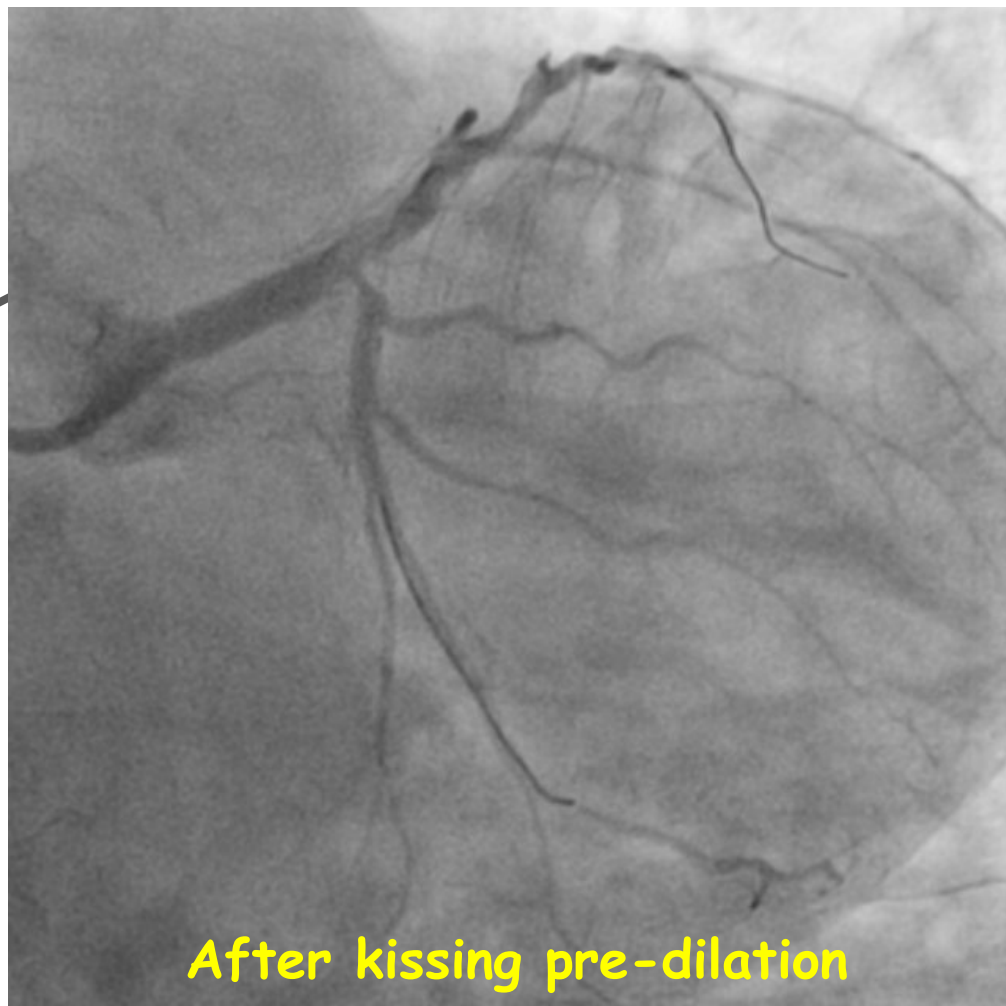
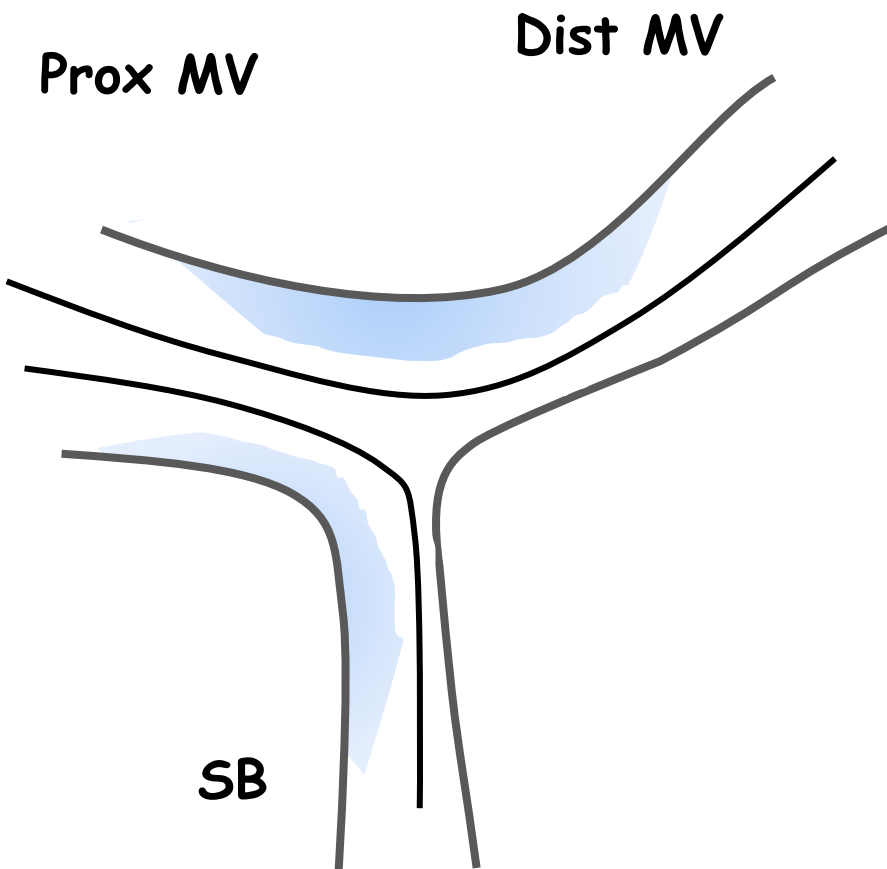
MINIMIZE THE RISK OF SB OCCLUSION



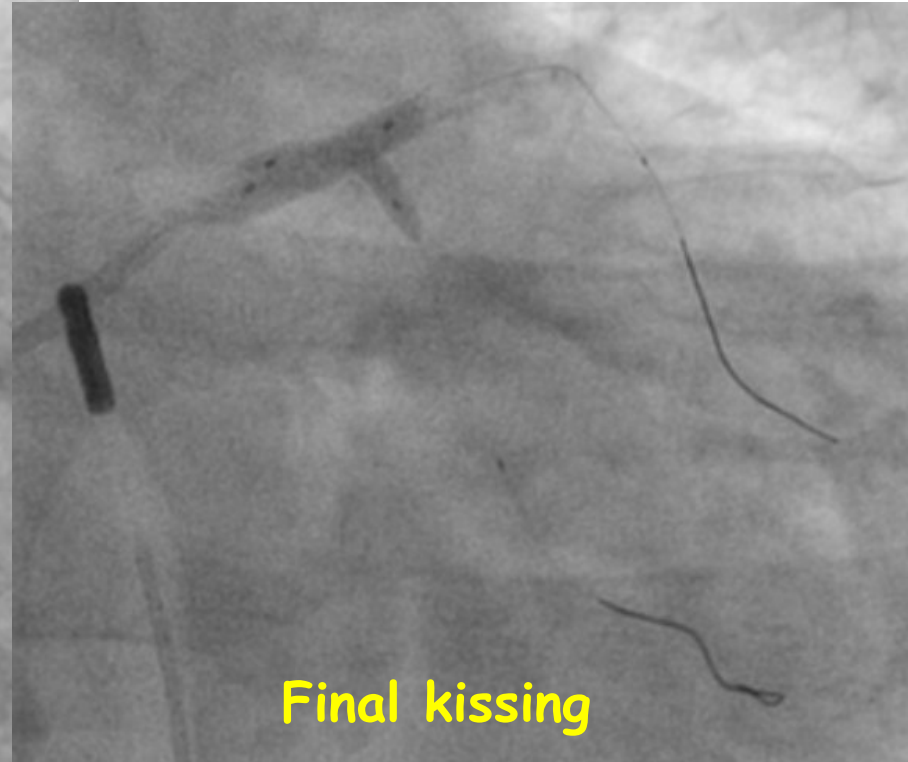
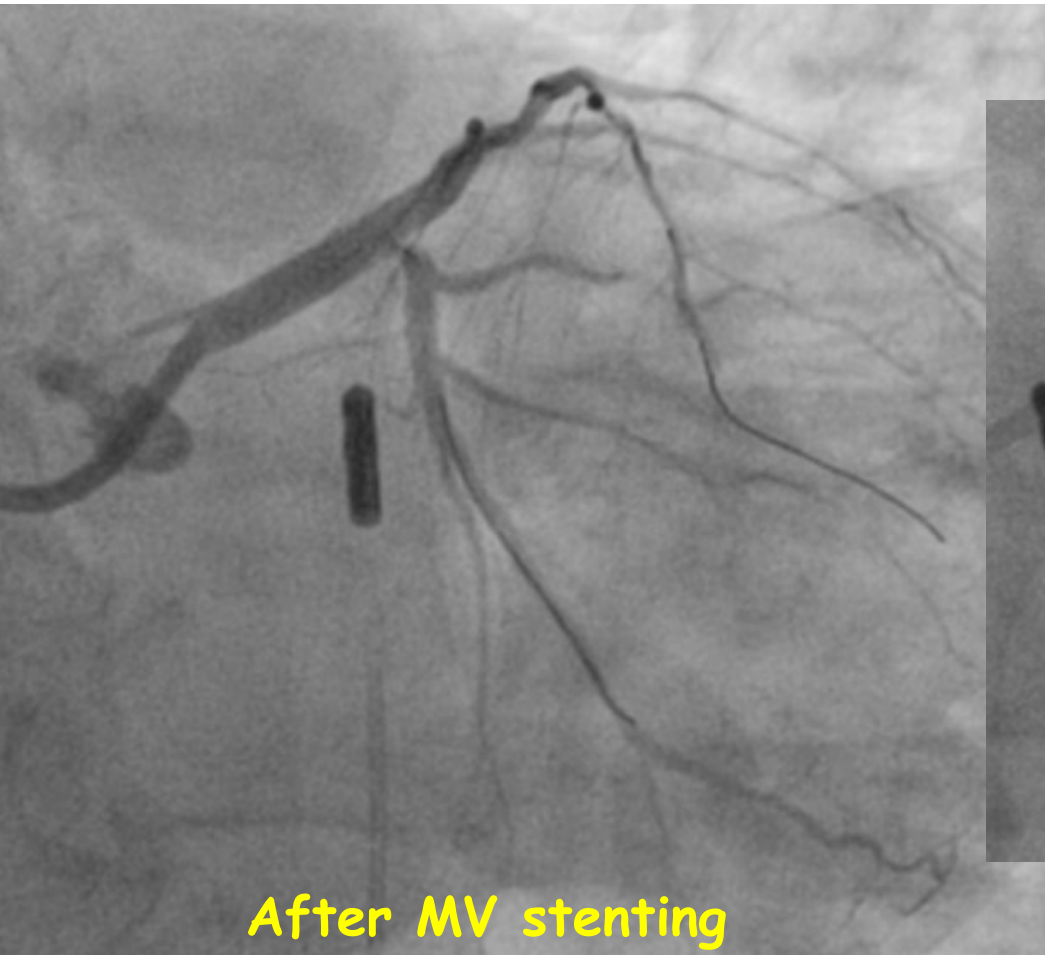
MINIMIZE THE RISK OF SB OCCLUSION



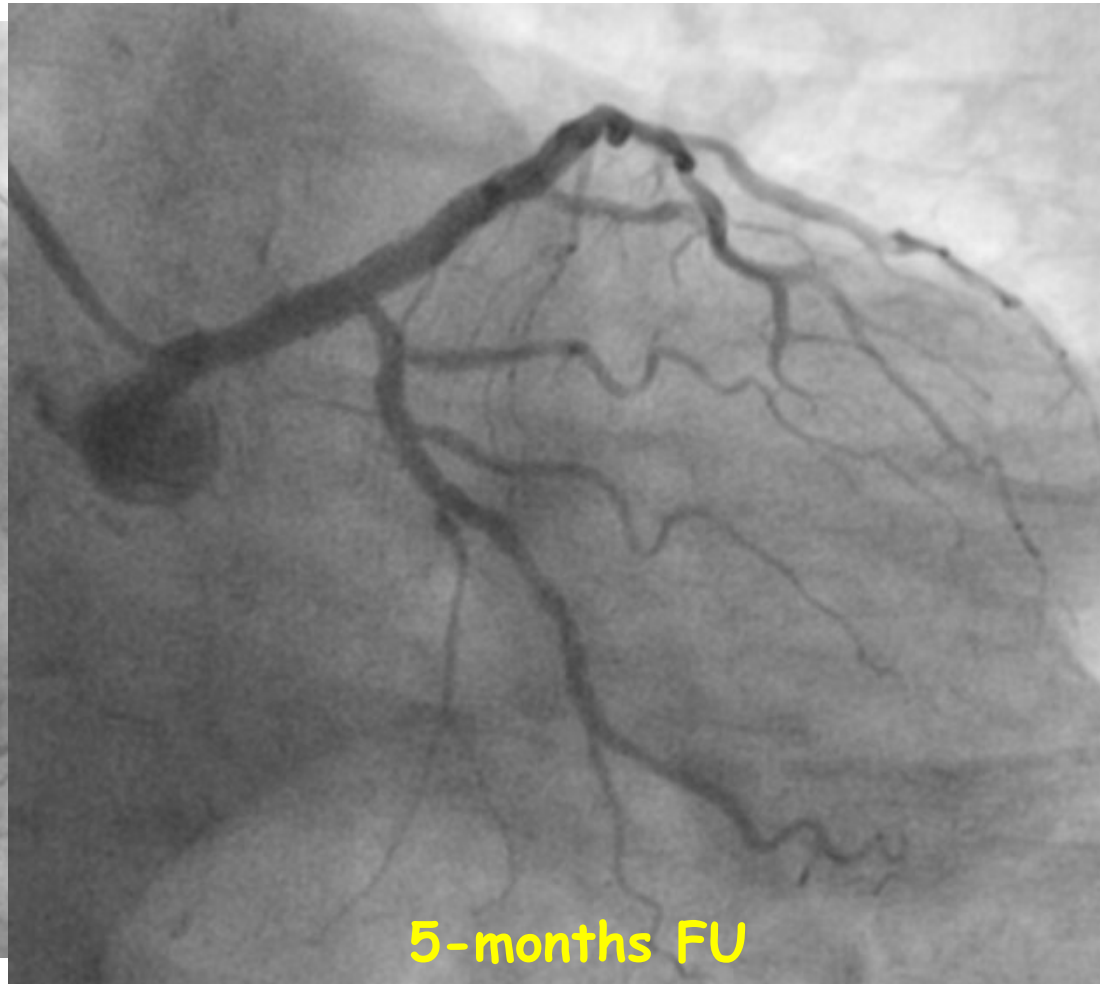
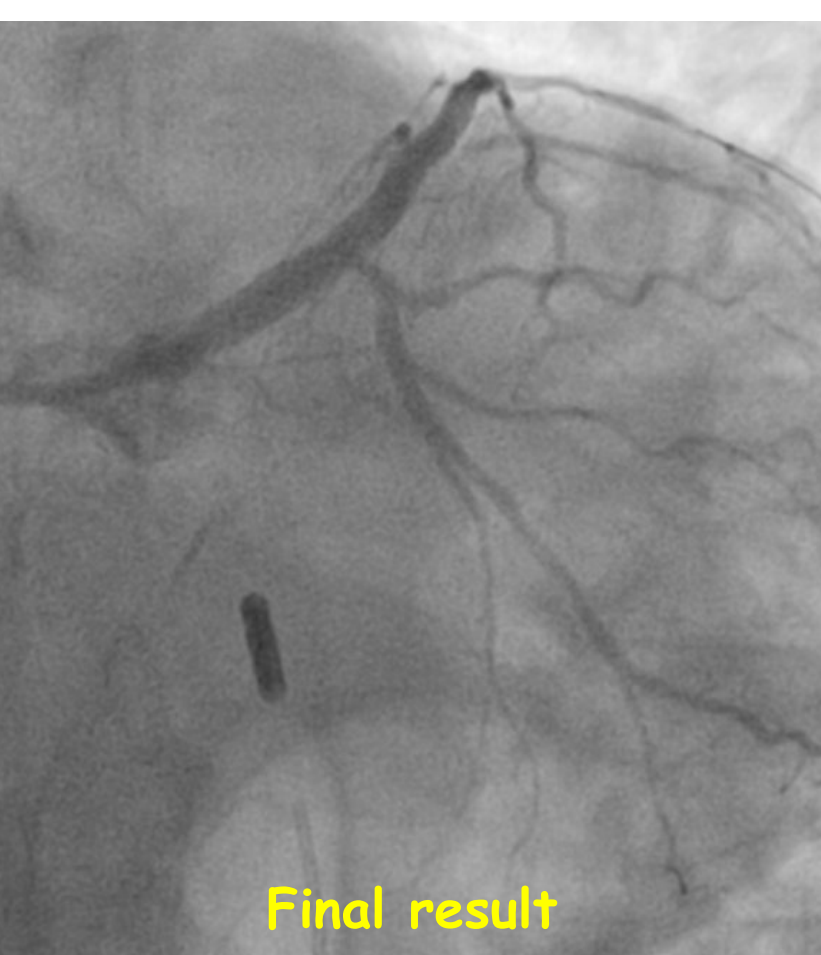MINIMIZE THE RISK OF SB OCCLUSION



MINIMIZE THE RISK OF SB OCCLUSION (IN 1 STENT STRATEGY)



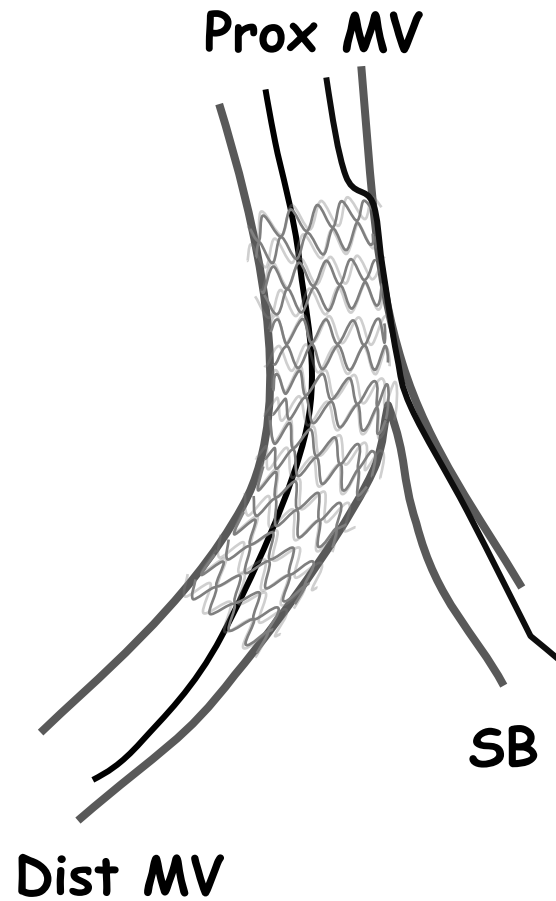
MINIMIZE THE RISK OF SB OCCLUSION (IN 1 STENT STRATEGY)



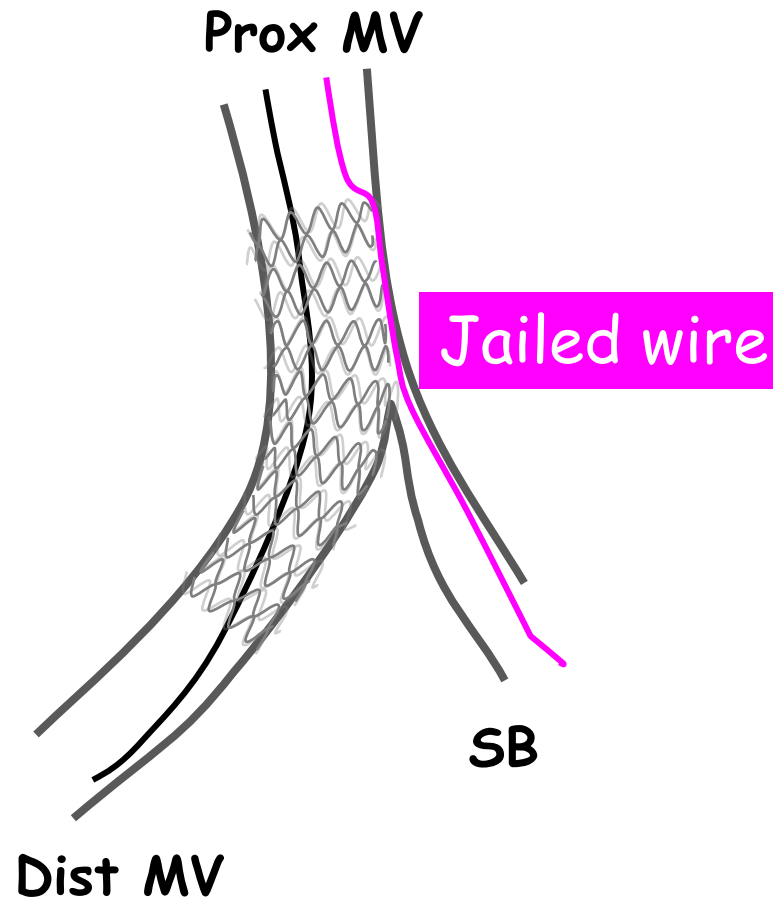
DOTATI DI UN PIANO DI SALVAGGIO !!!



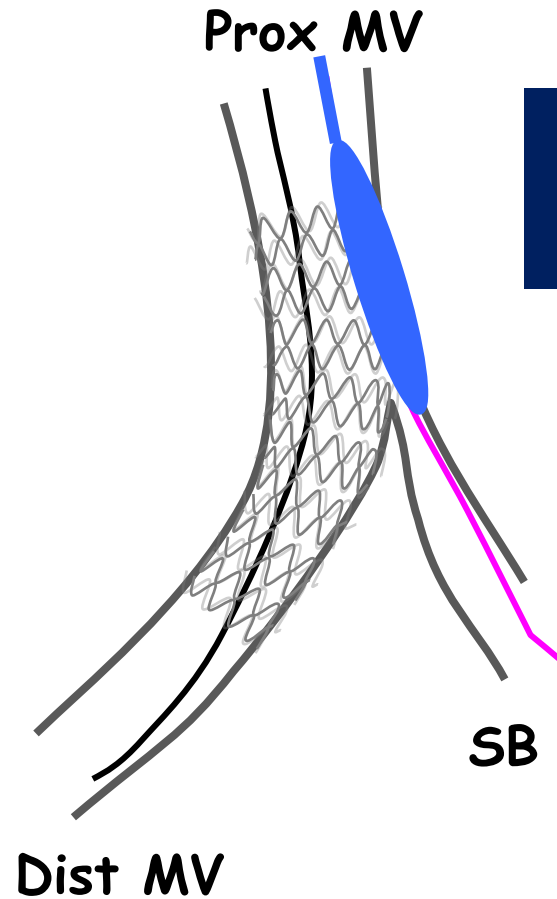
WHAT TO DO WHEN A LARGE JAILED SIDE-BRANCH IS ACUTELY OCCLUDED?



WHAT TO DO WHEN A LARGE JAILED SIDE-BRANCH IS ACUTELY OCCLUDED?

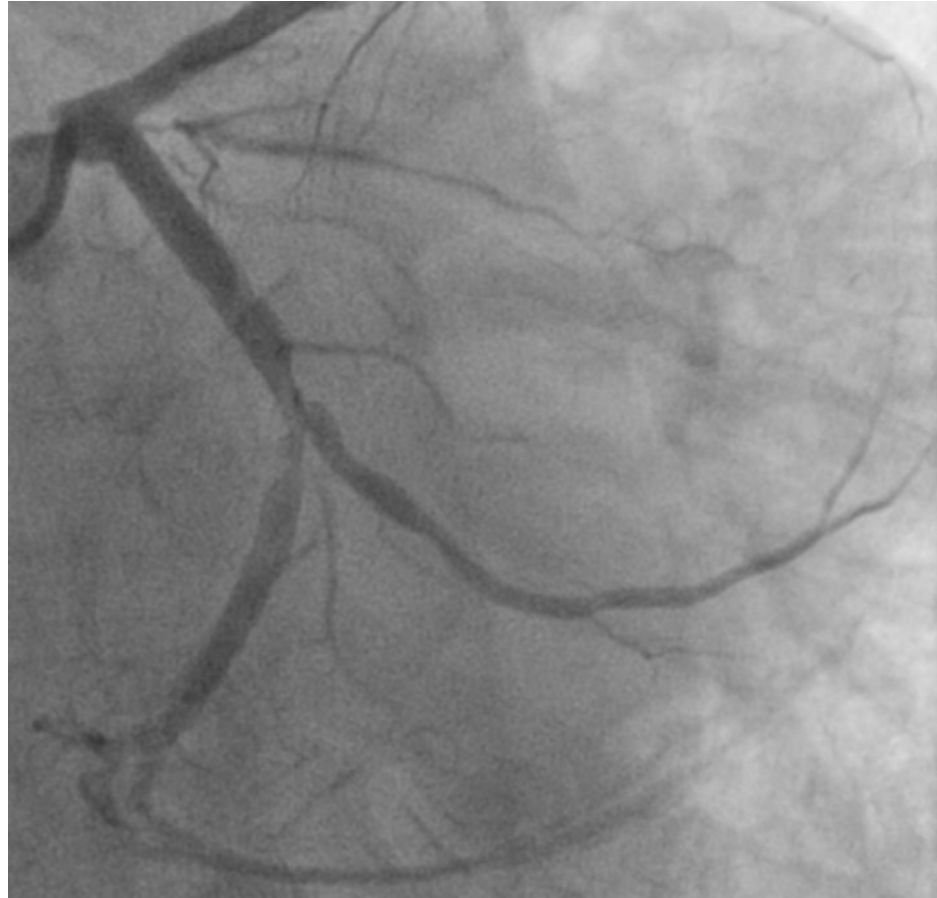

WHAT TO DO WHEN A LARGE JAILED SIDE-BRANCH IS ACUTELY OCCLUDED?

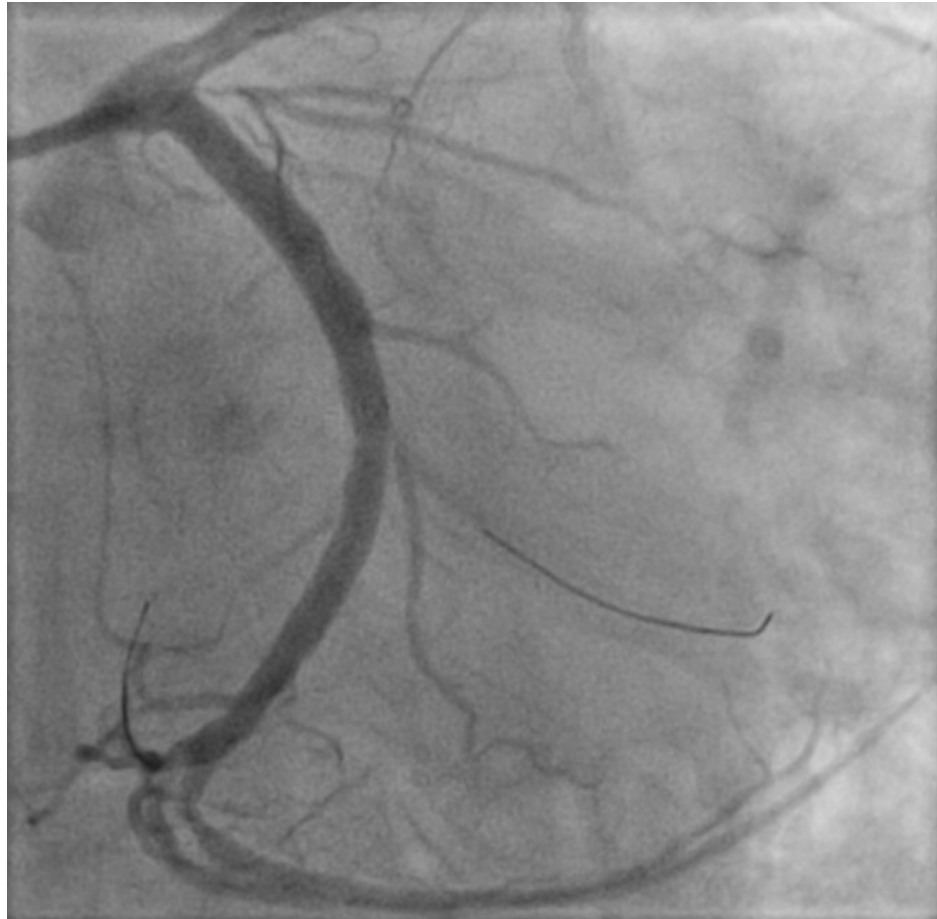

Rescue Balloon
Jailing Technique

WHAT TO DO WHEN A LARGE JAILED SIDE-BRANCH IS ACUTELY OCCLUDED?

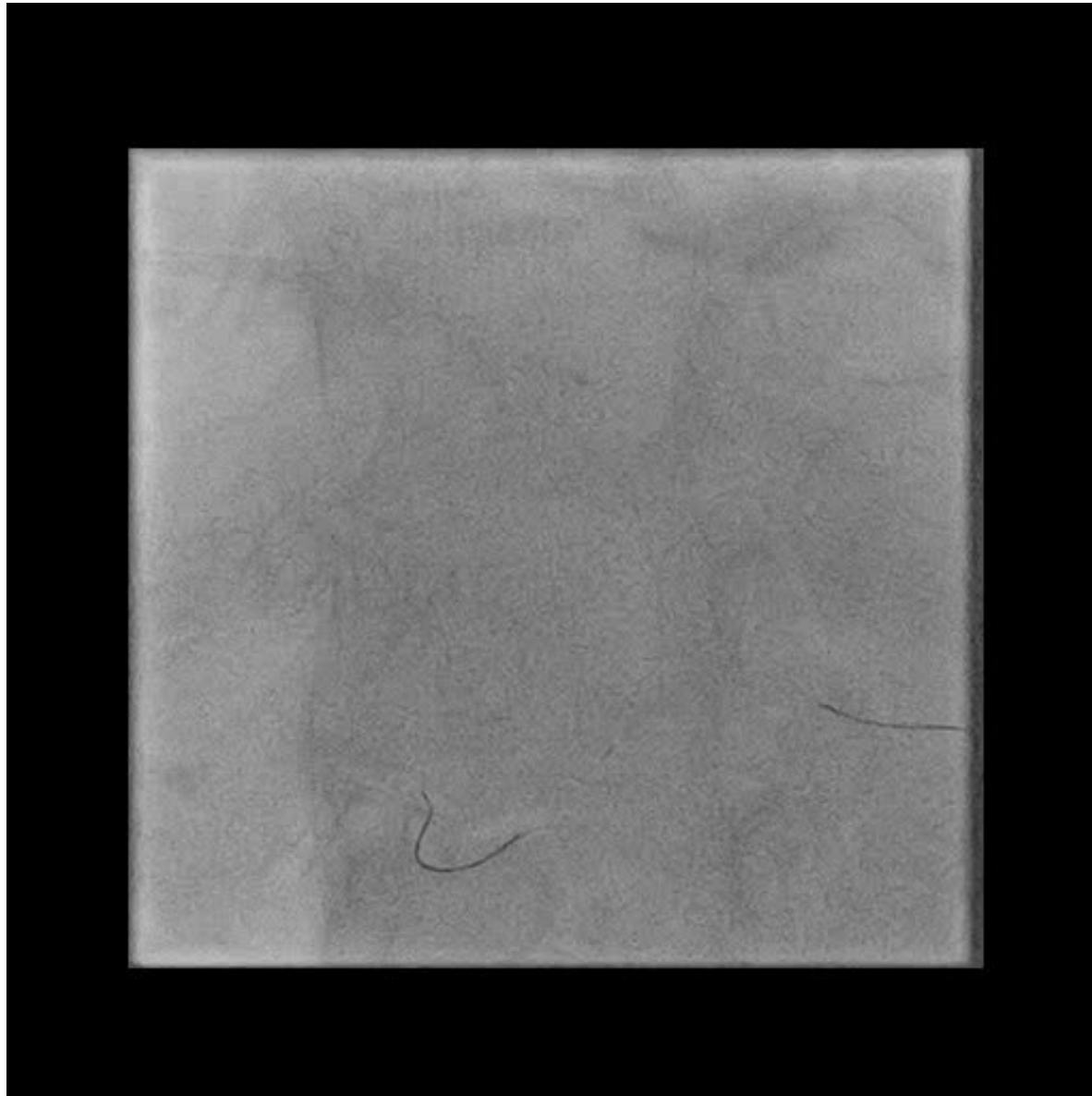


WHAT TO DO WHEN A LARGE JAILED SIDE-BRANCH IS ACUTELY OCCLUDED?

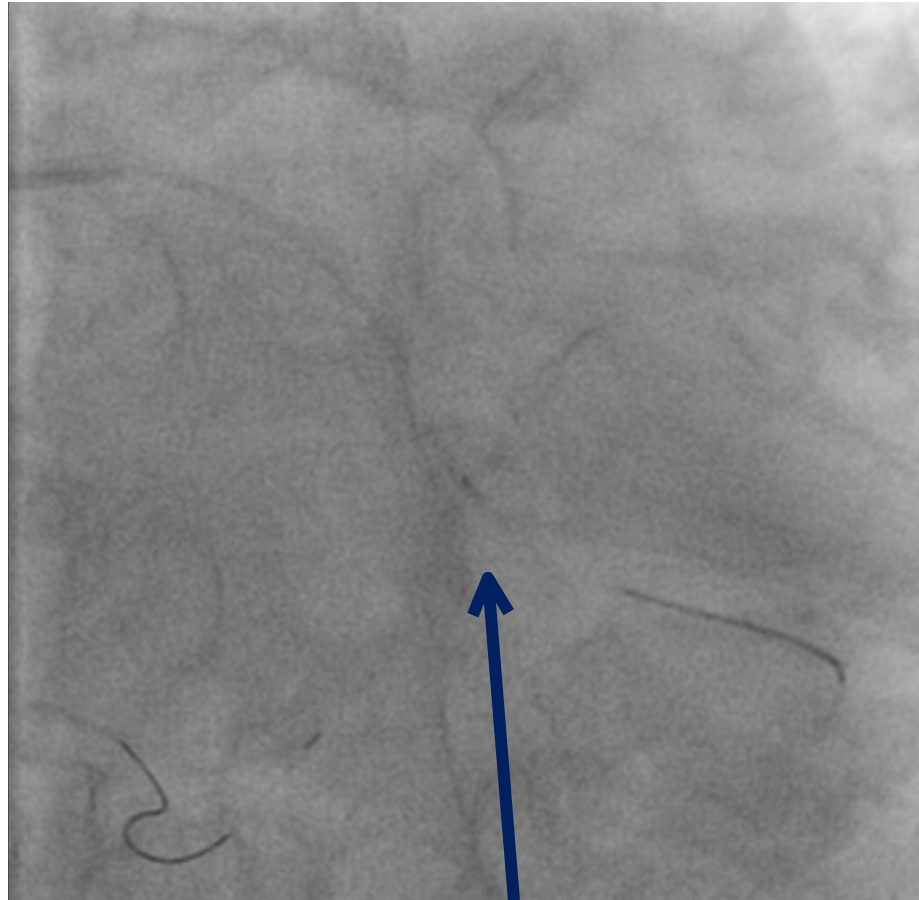


Chest pain and ST elevation after MV Stent and POT

WHAT TO DO WHEN A LARGE JAILED SIDE-BRANCH IS ACUTELY OCCLUDED?

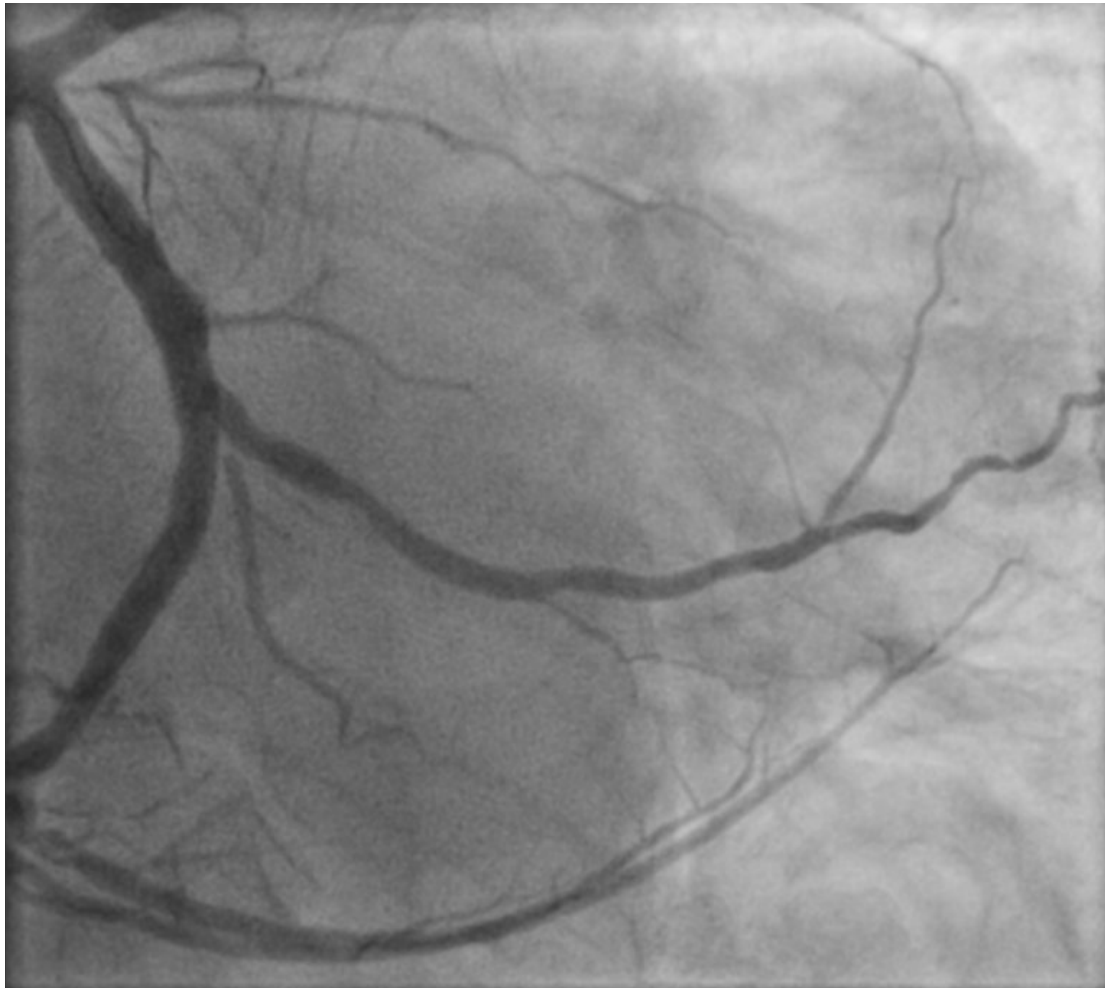

WHAT TO DO WHEN A LARGE JAILED SIDE-BRANCH IS ACUTELY OCCLUDED?



Rescue balloon inflated
over jailed wire

WHAT TO DO WHEN A LARGE JAILED SIDE-BRANCH IS ACUTELY OCCLUDED?



Final result

GRAZIE PER L'ATTENZIONE !!!



STAR
THE END
WARS