PLACE

PLATFORM OF LABORATORIES FOR ADVANCES IN CARDIAC EXPERIENCE

ROMA
Centro Congressi
di Confindustria
Auditorium
della Tecnica

9ª Edizione

30 Settembre
1 Ottobre
2022

COMPLEX PCI & PATIENT INTERACTIVE SYMPOSIA

LESIONI CORONARICHE CALCIFICHE: Quale device utilizzare e perché

Giovanni Luigi De Maria MD, PhD, FESC

Interventional Cardiology Consultant

Clinical Lead AMIIC Research Catheterization Laboratory – University of Oxford

Oxford Heart Centre – John Radcliffe Hospital

Oxford University Hospital – NHS Foundation Trust, Oxford UK

GiovanniLuigi.demaria@ouh.nhs.uk
@GiovanniLuigiD1
Giovanni Luigi De Maria

PLACE

PLATFORM OF LABORATORIES FOR ADVANCES IN CARDIAC EXPERIENCE

ROMA
Centro Congressi
di Confindustria
Auditorium
della Tecnica

9ª Edizione

30 Settembre
1 Ottobre
2022

Conflicts of Interest

Within the past 12 months, I have had a financial interest/arrangement or affiliation with the organization(s) listed below.

Affiliation/Financial Relationship	Company
Grant/Research Support	Miracor Medical SA, Abbott, Philips, Medtronic, Terumo
Consulting Fees/Honoraria	Miracor Medical SA, Abbott

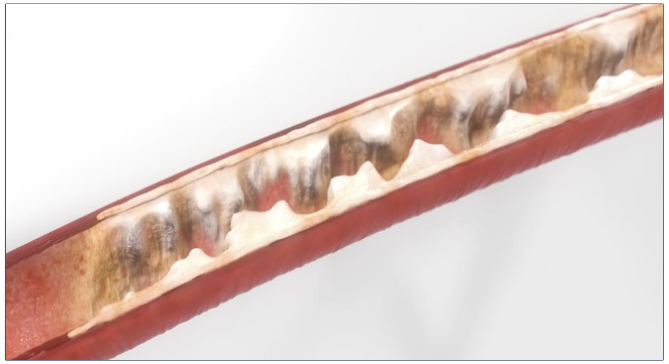

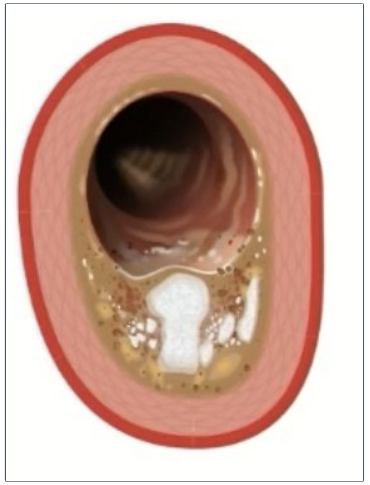

⇓ Compliance (distensibilita')

Calcific plaque is at least 4-5 times less compliant than cellular plaque

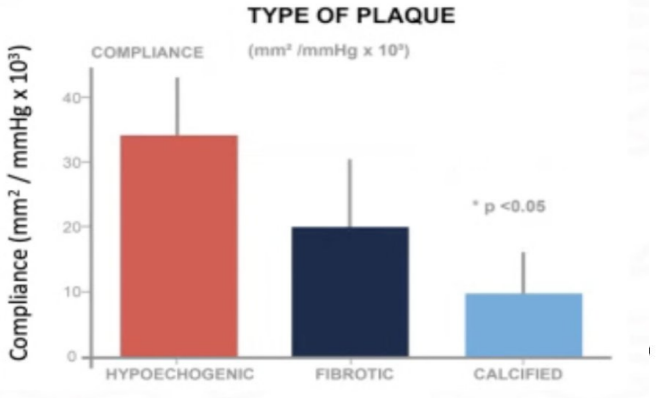

Reddy et al Am J Cardiol 1993

Danno Stent/Polimero

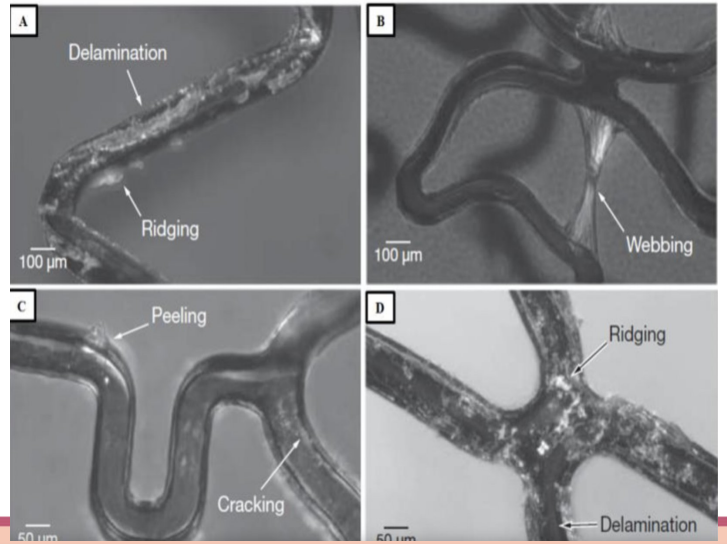

Stent Malapposition

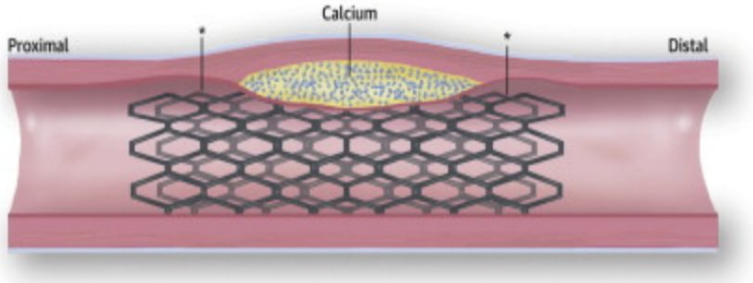

Stent Underexpansion

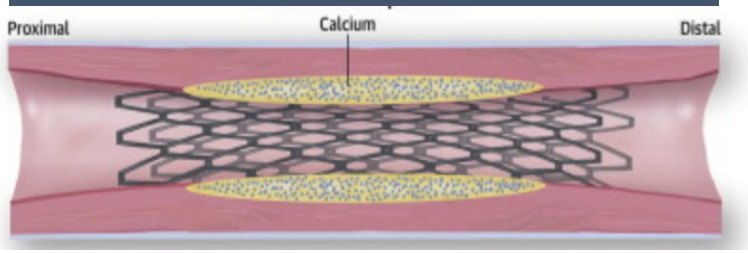

Cinetica di Drug Elution alterata

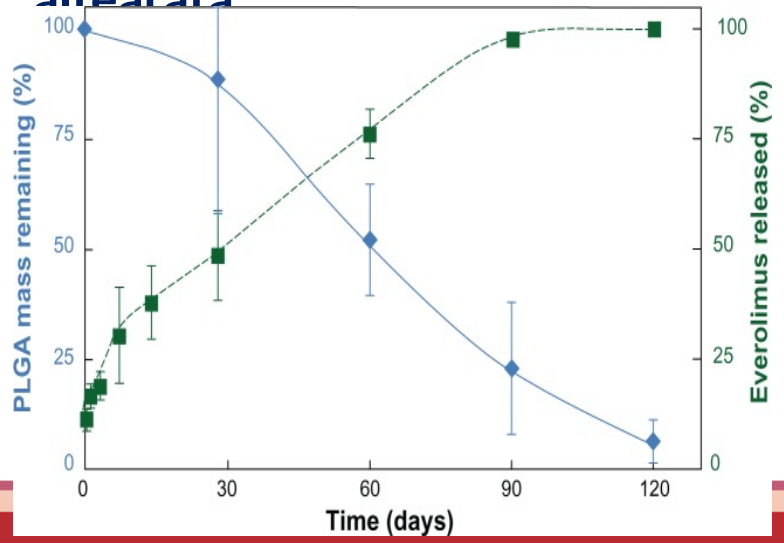

Obiettivo
Aumentare Compliance del Vaso

"Displacing" Calcio

Palloni Non complianti
Palloni alta pressione

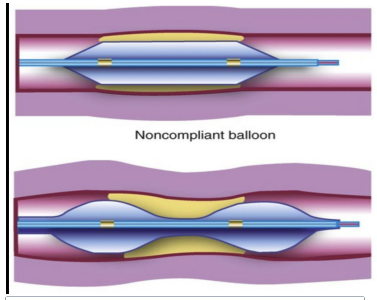

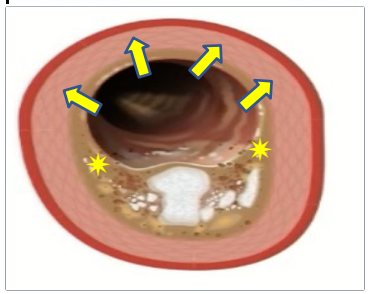

Modificare componente Calcifica

Cutting Calcium
(fibrotic tissue around calcium)

Scoring/Cutting Balloons

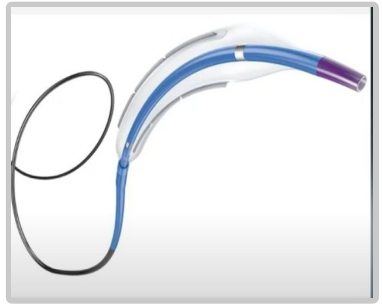

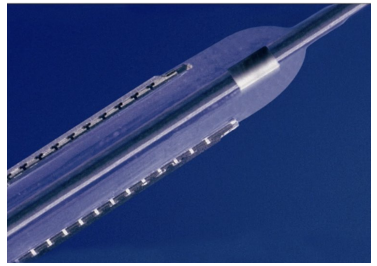

Cracking Calcium

Intravascular lithotripsy

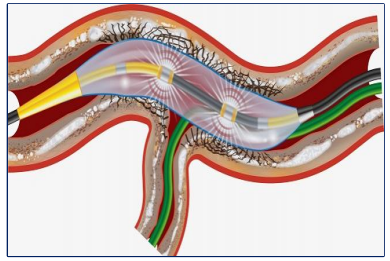

Ablating Calcium

Rotational Atherectomy

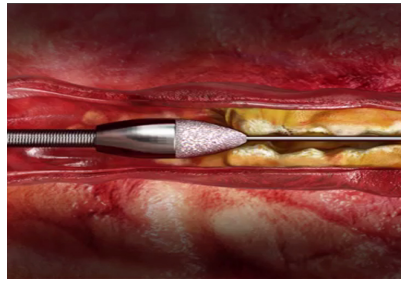

Orbital Atherectomy

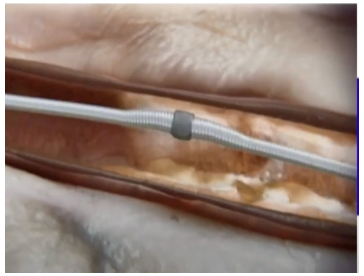

Laser

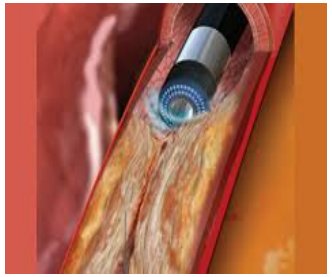

Quale device utilizzare e perché

1) ***"Cross-ability" della lesione con Pallone o intravascular imagining catheter (OCT o IVUS)***

No -- > Tecniche di Ablazione

2) ***Pattern di distribuzione del calcio***

3) ***Capire come ciascun device funziona e su quale pattern di calcio ciascun device agisce meglio***

Patterns di Calcio Coronarico

Eccentricita'

Arco di calcio
(gradi (°) o quadranti)

- Calcio eccentrico
- Calcio concentrico
- Anello di calcio (360°)



Profondita'

Distanza dal lume

- Protruding (*"nodulo"*)
- Superficiale
- Profondo



Spessore

Max Spessore di Calcio

- Sottile
- Spesso

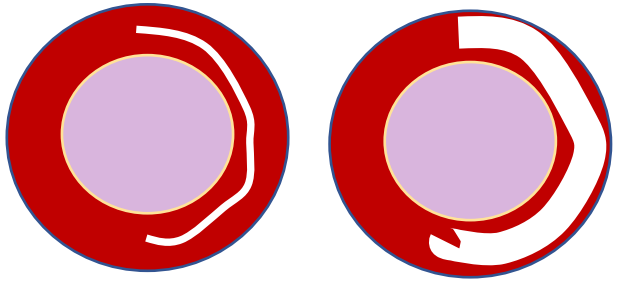

Lunghezza

Estensione Longitudinale

- Focale
- Diffusa

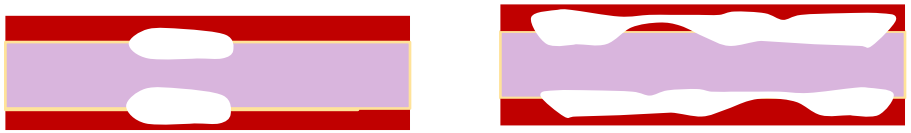

Palloni Non complianti / Palloni alta pressione

Displacing Calcium

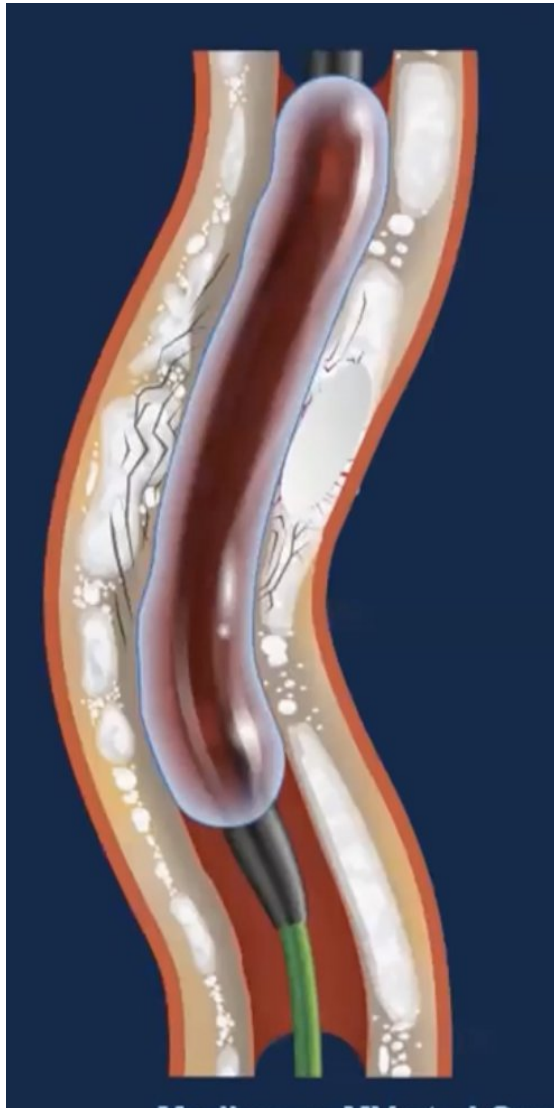

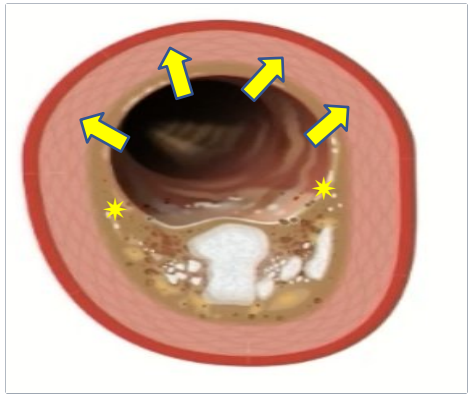

Spostano via ("push-away) il calcio, senza modificarlo

Agiscono sulla parte "soft" della parate vasale

Pros

"Low Cost"

Ok per calcio eccentrico & sottile

Metodo per valutare vessel-compliance dopo "advanced lesion modification" prima di impianto dello stent

Cons

Limiti su calcio concentrico e spesso

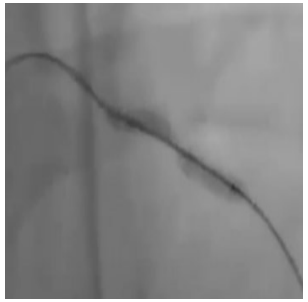

"Unpredictable" meccanismo di azione, specialmente in presenza di noduli calcifici o calcio profondo

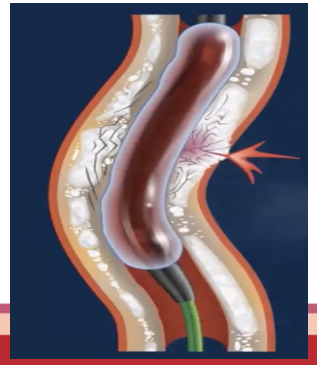

Cutting Balloons

1) Non compliant
2) Pressione nominale 6 atm (RBP 12 atm)
3) Crossability migliorata con device di ultima generazione
4) Incisioni Microchirurgiche
5) "Steak Knife" action

"lama appuntita e affilata"

Tagliare calcio *(>> Tessuto fibrocalcifico)*

Scoring Balloons

1) Semi compliant
2) Smaller profile rispetto a cutting balloon
3) Pressione nominale 8 atm (RBP 16-18 atm)
4) Incisioni Microchirurgiche
5) "Butter Knife" action

"lama piatta"

Incidere calcio *(>> Tessuto fibrocalcifico)*



Scoring & Cutting Balloons

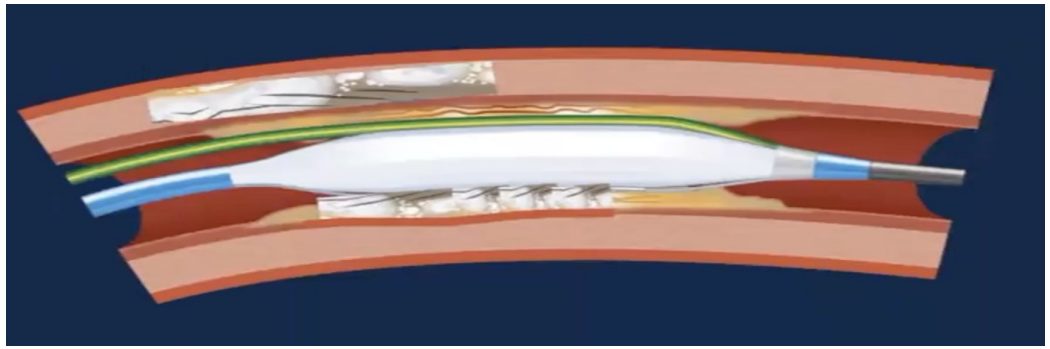

Pros

Modificano componente fibro-calcifica e contribuiscono a migliorare compliance vaso

Device aggiuntivo a tecniche di modifica-calcio avanzate

Ok per calcio eccentrico & sottile
(specie se gia' modificato da altre tecniche)

Cons

Limiti su calcio concentrico e spesso

No azione su calcio profondo

Deliverability

Costo *(in UK 50% cost of IVL/Rota)*

Intravascular lithoplasty

Cracking Calcium

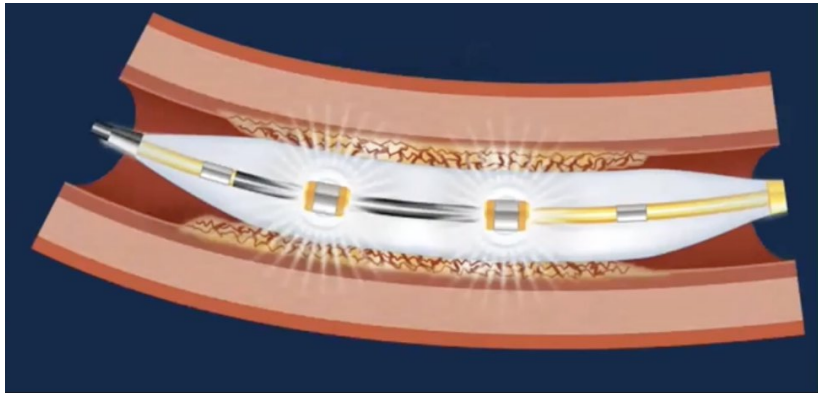



1) Balloon-Based technique
2) Due emittirori in IVL coronarico
3) Pallone da 12 mm in lunghezza (2.5 – 4.0 mm ⌀)
4) Modalita' di azione
   a. Corrente elettrica passa nei due emettitori
   b. Generazione di bolle
   c. Produzione di sonic wave (shockwave)

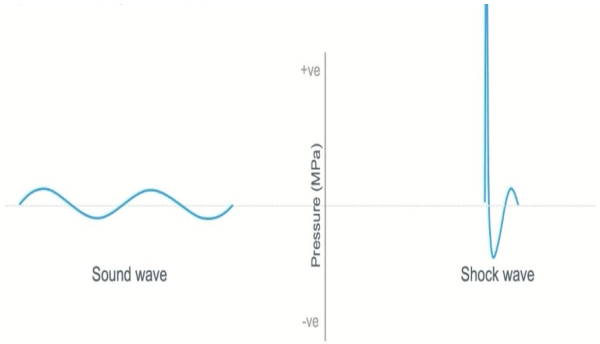



"Hard on Hard

Soft on Soft"

Intravascular lithoplasty

Cracking Calcium

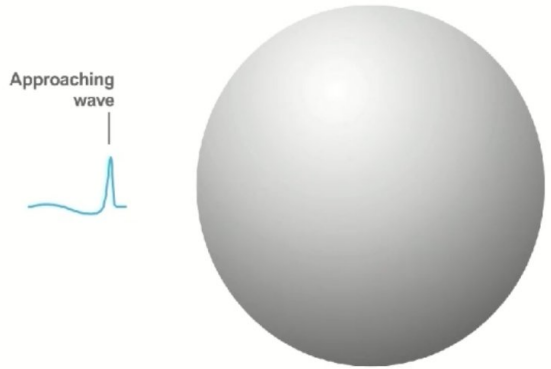

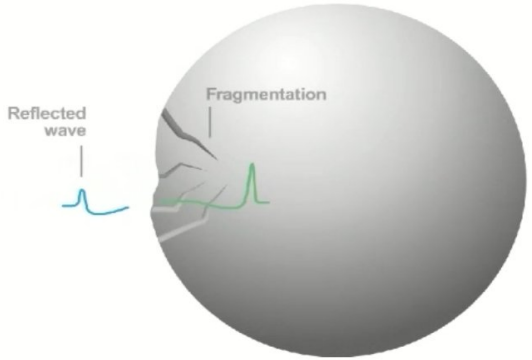

Compression

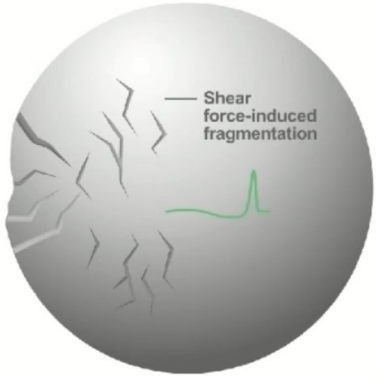

Shearing

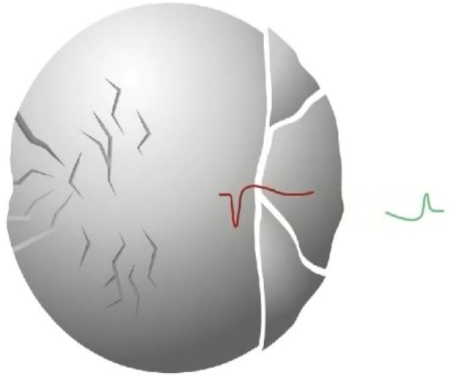

Spallation

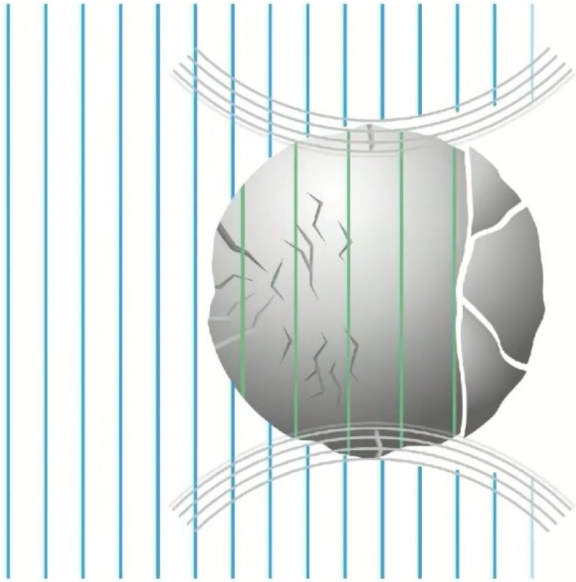

Squeezing

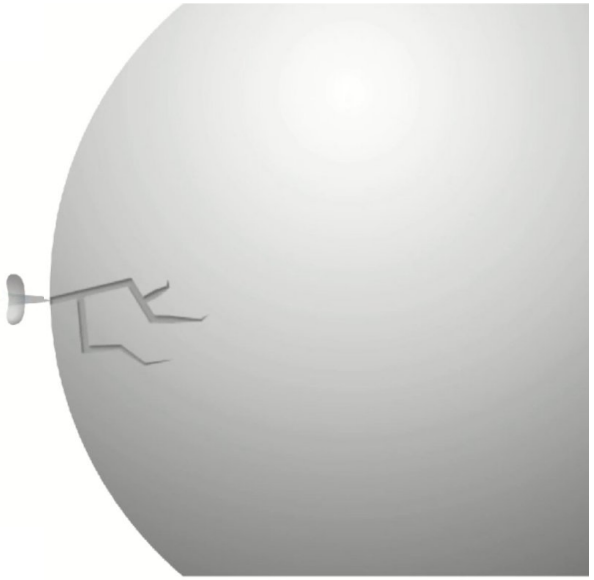

Cavitation

Intravascular lithoplasty

Cracking Calcium

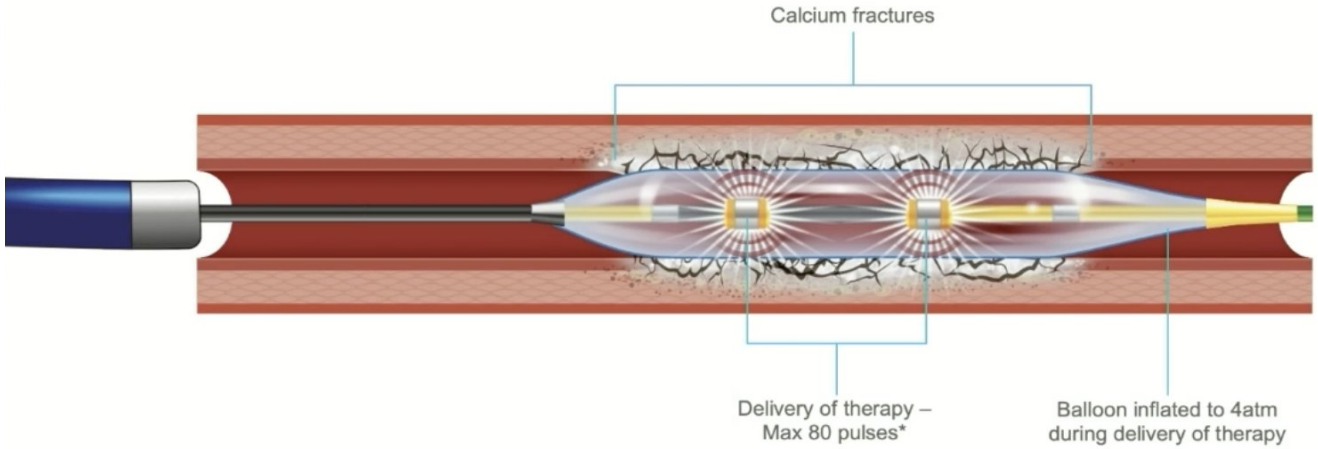

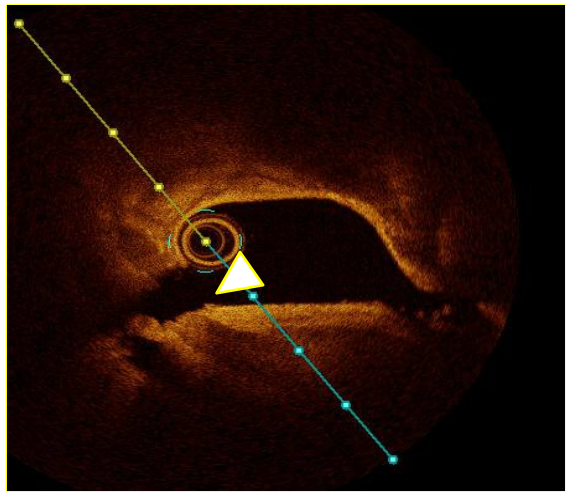

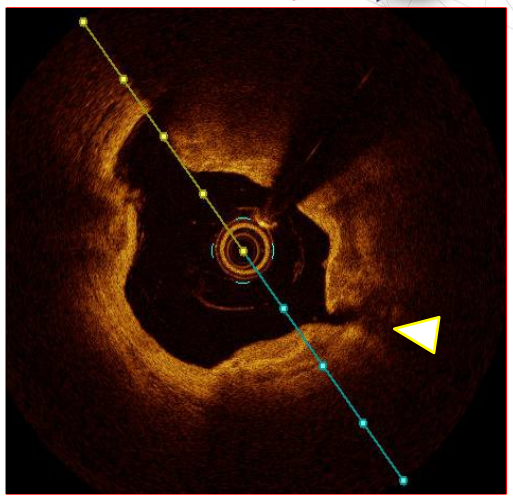

Pros

Steep or NO Learning curve

Efficace su calcio Spesso

Efficace su calcio superficiale e profondo

Efficace su calcio circonferenziale >> eccentrico

Side-Branch protection possibile

Limitato rischio di distal embolization (vs tecniche ablative)

- application in STEMI / lesioni trombotiche

Cons

Profilo del Pallone – Limitata Crossability/Trackability

Limitata efficacia su calcio eccentrico

Limitata efficacia su noduli calcifici

Costo

Aterectomia Rotazionale (Rotablation)

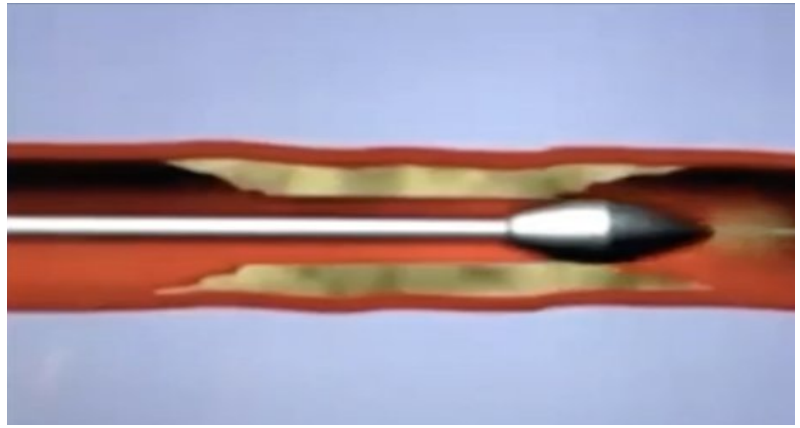

- **Azione ablativa dalla combinazione di**
  - *Cutting element – diamond coating*
  - *Calore generato da Rotazione ad alta velocita'*
- **Recente reiterazione**
  - *Rota / dyneglide functions integrati su advancer*
  - *Nuova console con messaggi visivi*
  - *Gas e fibra-ottica integrate su stesso cavo*
- **Azione e' prevalente su calcio luminale**
- **Possibile azione su noduli calcifici**

Ablating Calcium – Digging Effect

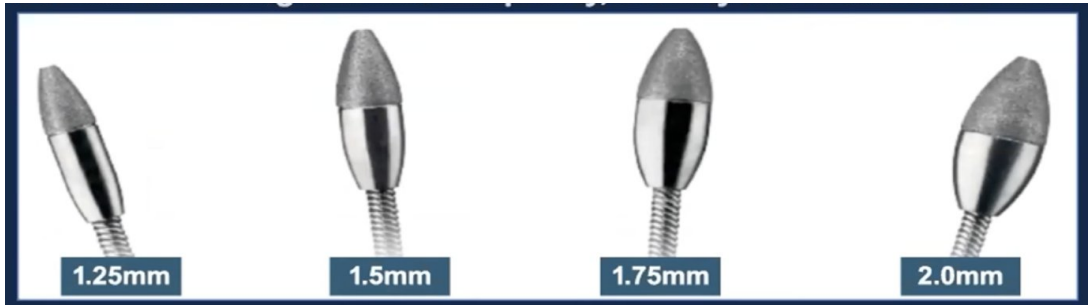

Burr Size (mm)	Guide Catheter Internal Diameter		
	6F (0.070")	7F (0.081")	8F (0.091")
1.25	0.049"	0.049"	0.049"
1.5	0.059"	0.059"	0.059"
1.75	0.069"	0.069"	0.069"
2.0	0.079"	0.079"	0.079"

Aterectomia Rotazionale (Rotablation)

Ablating Calcium – Digging effect

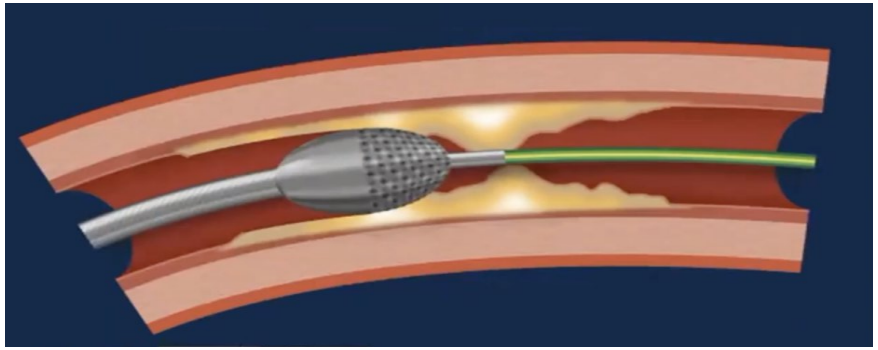

Pros

Risolve problematica di “uncrossable” stenosi

Efficace su calcio superficiale e concentrico

Possibile efficacia per noduli calcifici
- Wire Bias
- Max Rota technique

Cons

Limitata efficacia su calcio eccentrico

Limitata efficacia su calcio profondo

Cautela in tortuosita’ estreme

Rischio di embolizazzione distale / no reflow

Learning curve

Costo

Aterectomia Orbitale (Orbital Atherectomy)

Ablating Calcium – Sanding effect

1.25 mm crown
"1 size fits all"

- **Azione ablativa – "Sanding away the calcium"**
  - *Both antegrade and retrograde ablation*
- **Sistema comprende**
  - *Advancer*
  - *1,25 mm crown (6 F compatibile)*
  - *0.014" filo-guida (Viper Guidewire)*
  - *Soluzione lubrificante (Viper) + Infusore dedicato*
- **Azione e' prevalente su calcio luminale**
- **Possibile azione calcio eccentrico e su noduli calcifici**
- **Ipotetica azione su calcio profondo (via mechanic waves)**

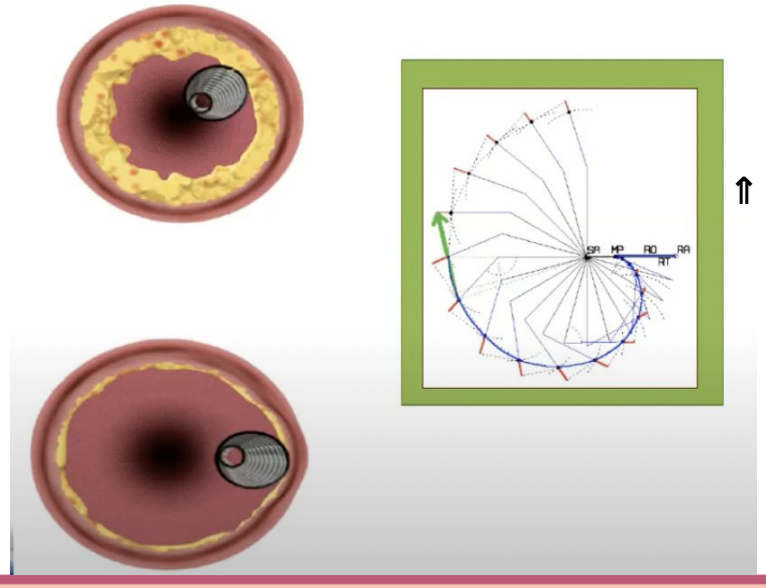

⇑ Velocita' di rotazione
Orbite piu' ampie
Azione su strati profondi di calcio

Aterectomia Orbitale (Orbital Atherectomy)

Ablating Calcium – Sanding effect



Pros

Risolve problematica di “uncrossable” stenosi

Teoretica Efficacia su calcio concentrico ed eccentrico

Teoretica efficacia su noduli calcifici

Ideale per vasi calcifici di ampio calibro o ectatici

“1 size fits all”

Ablazione anterograde e retrograde con Basso rischio di entrapment

Viper wire 0.014” ha proprieta’ simili a work-horse wire

Cons

Limitata evidenza clinica (… per ora)

Limitata efficacia su calcio profondo

Cautela in tortuosita’ estreme (… ma safety-profile > rotablation)

Rischio di embolizazzione distale / no reflow

Learning curve

Costo

Laser Atherectomy

Ablating & Cracking Calcium

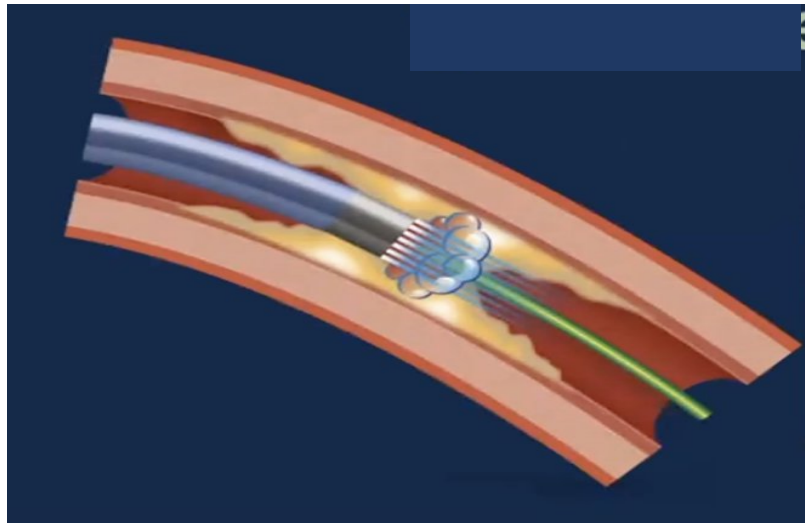

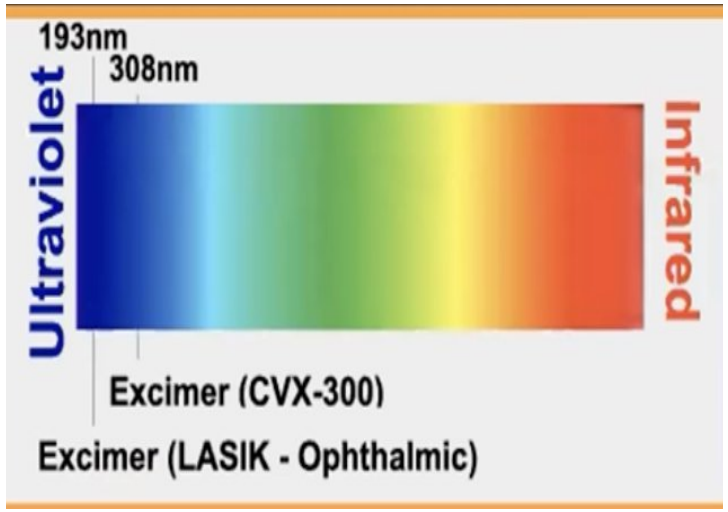

Meccanismi d'azione

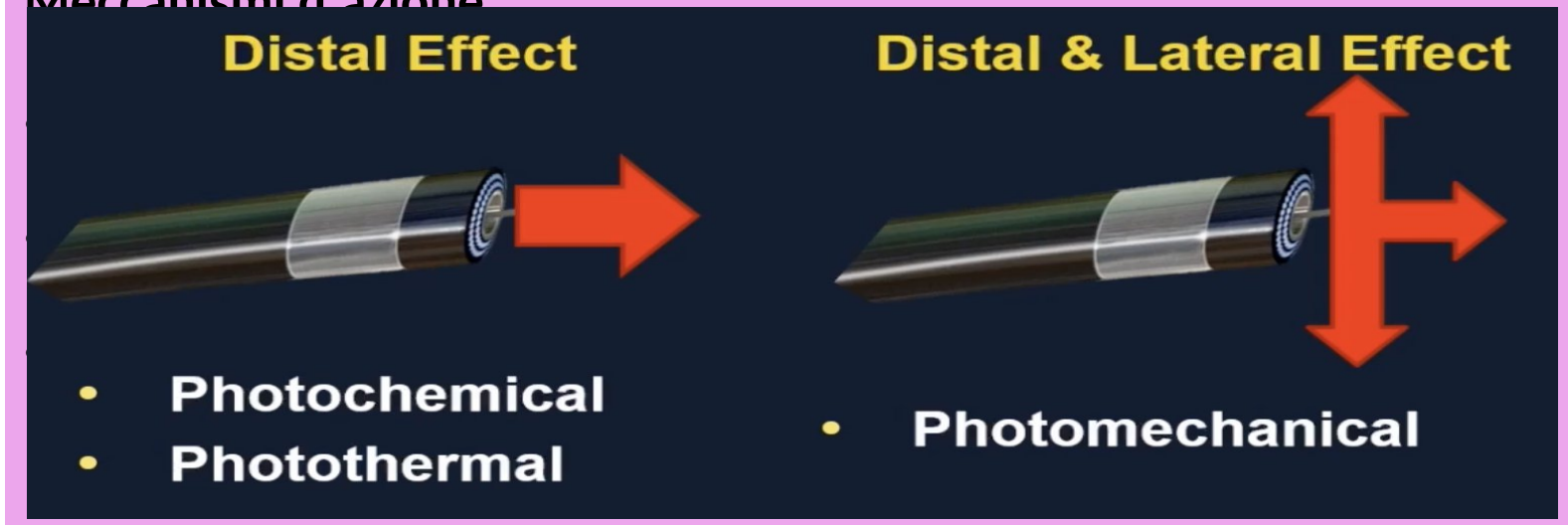

Ablazione placca aterosclerotica

Frattura componente calcifica



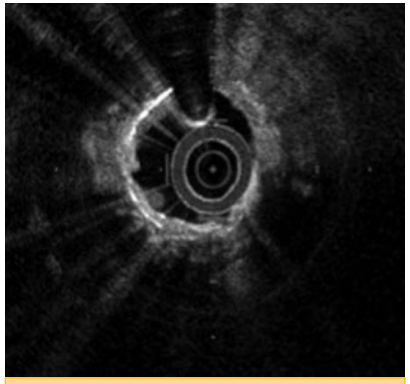

Stent sotto-espanso & non dilatabile dopo rotablation

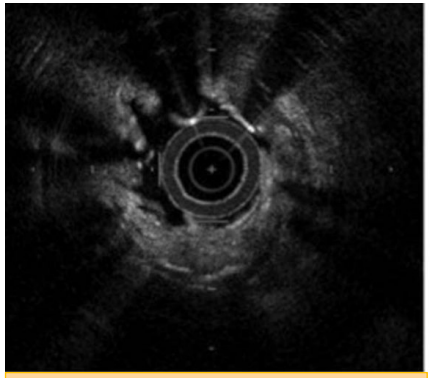

Dopo ELCA con salina

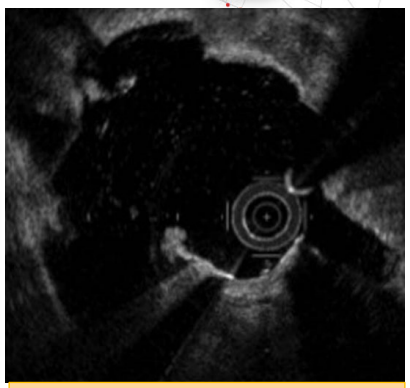

Dopo ELCA con m.d.c.

Ashikaga et al CCI 2015

Pros

Efficace in uncrossable lesions

Ideale in instent-ristenosi calcifiche non dilatabili

Effetto fotomeccanico consente azione su calcio fino ad una profondita' di 400-500 micron

Cons

Learning Curve

Costo

Limitata diffusione – non disponibile in ogni cathlab

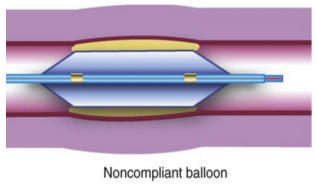

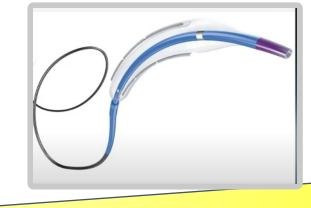

Uncrossability

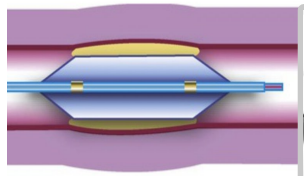

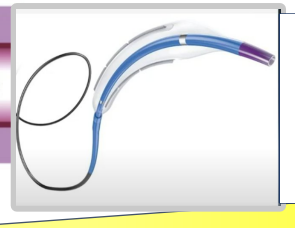

Eccentricity

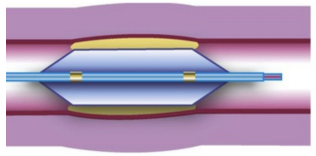

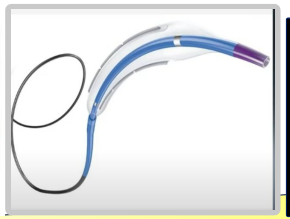

Depth

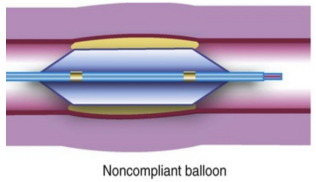

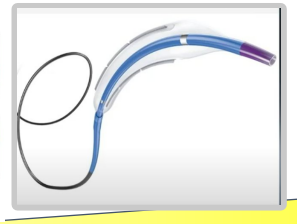

Thickness

CENTRAL ILLUSTRATION: Algorithm for Optimal Management of Coronary Calcified Lesions

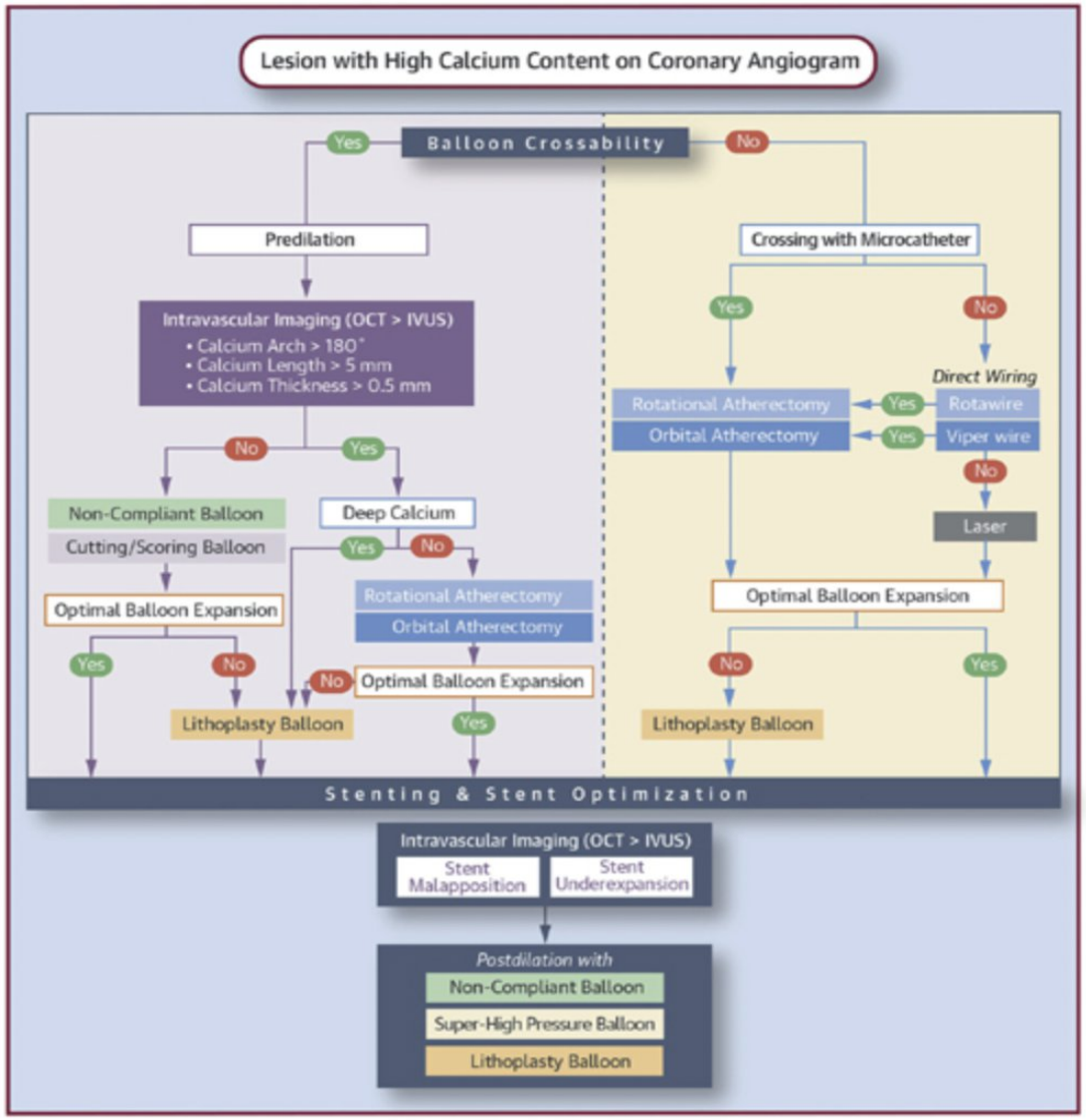

De Maria, G.L. et al. J Am Coll Cardiol Intv. 2019;12(15):1465-78.

MY TOOLBOX FOR CALCIFIED CORONARY DISEASE

Thin & Superficial Calcium

NC balloon
or
Cutting / Scoring Balloons
or
Super High Pressure Balloons

Intravascular Imaging

IVUS (aorto-ostial lesions)

or

OCT

Uncrossable Stenosis

Rotational Atherectomy
or
Orbital Atherectomy

+/-

Laser

Calcific Nodule & Eccentric Calcium

Thick & Deep Calcium

Intravascular lithoplasty

Conclusioni

- Lesioni calcifiche = marker e causa di complessita' procedurale
- Aumentato rischio di stent failure
- Imaging Intravascolare(IVUS/OCT) gold standard per definire il burden calcifico e pattern di distribuzione
- Vasta gamma di tecnologie per modificare e preparare lesioni calcifiche
- Selezione basata
  - Lesion crossability / Pattern di calcificazione / Modalita' di azione del device
- Imaging-Based Algorithm puo' garantire
  - Approccio standardizzato / Outcome ottimale / Minimizzare complicanze, tempi e costi procedurali

Calcificazioni Coronariche

Paziente Complesso

- Anziano / Fragile
- Insufficienza renale
- Diabete
- Comorbidita'
- Patologie Valvolari *(stenosi aortica)*

Anatomia Complessa

- Malattia Multivasale
- ⇑ Burden di Placca
- Aterosclerosi Diffusa
- +/- Tortuosita'
- CTO
- Lesioni ostiali

Procedura Complessa

- Preparazione lesione
- Difficile crossing device
- Extra tempo procedural
- Extra esposizione X-ray
- Extra volume di mezzo di contrasto

⇑ Complicanze intraprocedurali

Risultato breve-medio termine suboptimale

Prognosi sfavorevole

Imaging & Calcium Pattern

	Eccentricita'	Profondita'	Spessore	Lunghezza	Quantificazione Burden Calcifico	Valutare Ca modification	Stent expansion & apposition
	V	V	V	V	X	X	X
	X	X	X	X	V	X	X
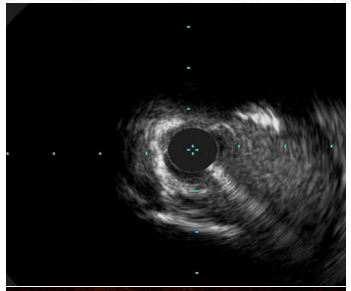	V	V	V	V	V	V	V
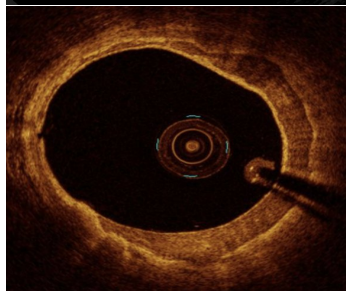	V	V	V	V	V	V	V

MAX-ROTA technique (Multi AXial Rotablation)

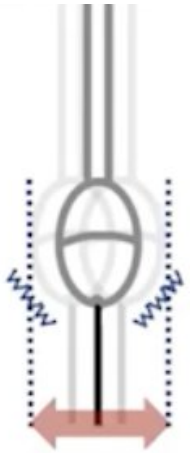

High rotational speed

(> 160k rpm)

Lower rotational speed

(140k – 160k rpm)

Narrow Rotablation Area

Large Rotablation Area

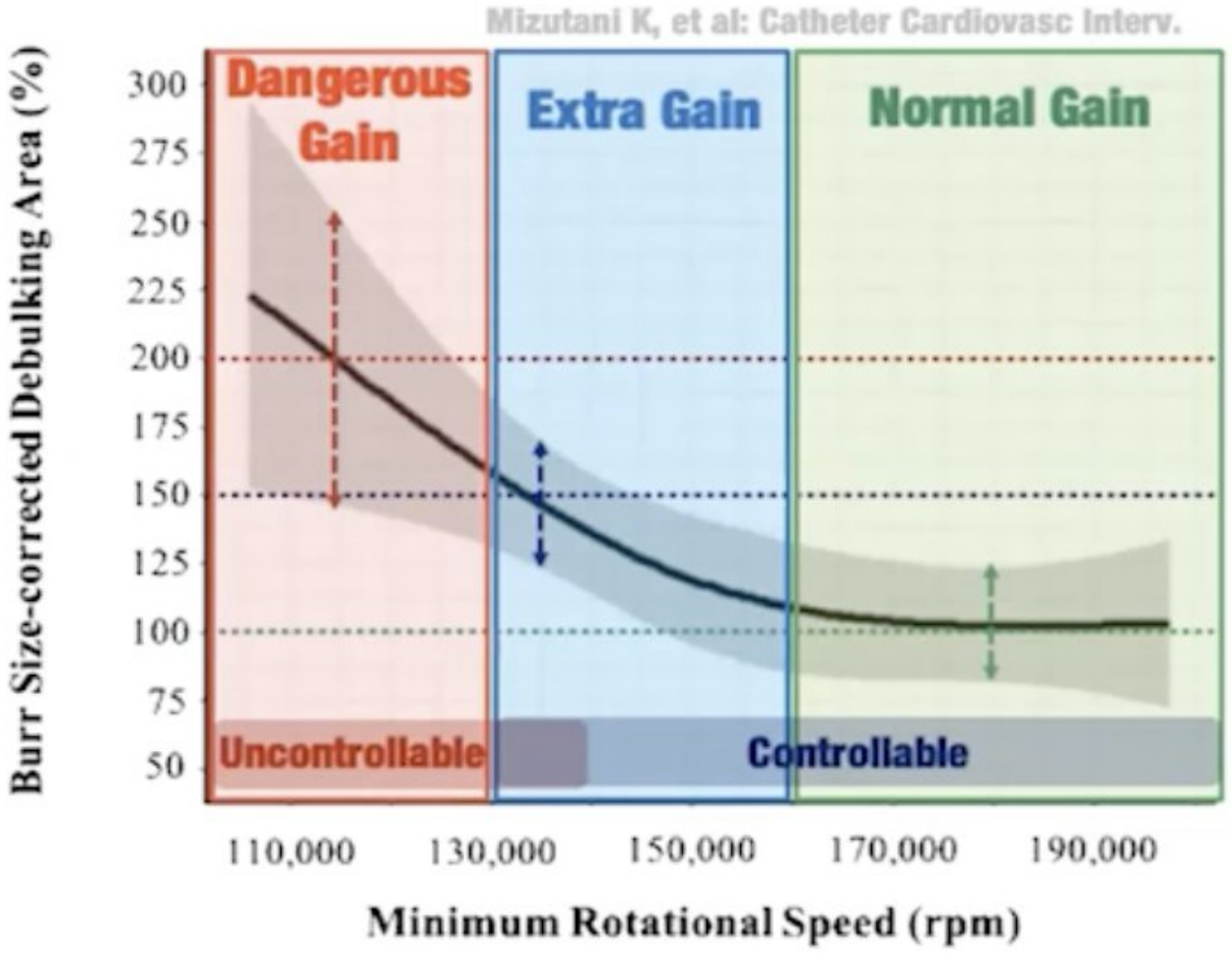

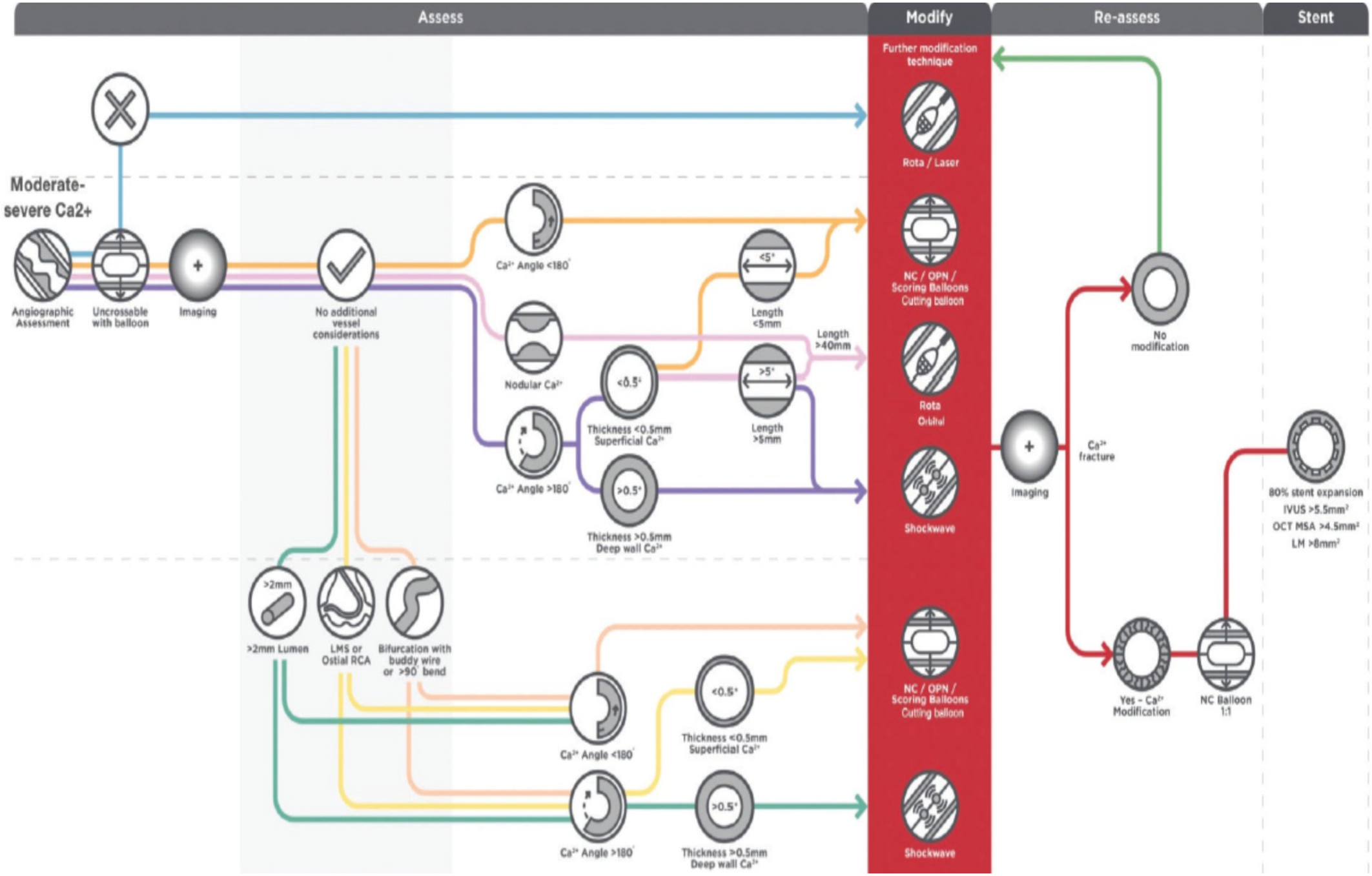
Assess
Modify
Re-assess
Stent
Moderate-severe Ca2+
Angiographic Assessment
Uncrossable with balloon
Imaging
No additional vessel considerations
Ca2+ Angle <180°
Nodular Ca2+
Ca2+ Angle >180°
<5°
Length <5mm
>5°
Length >5mm
Length >40mm
<0.5°
Thickness <0.5mm Superficial Ca2+
>0.5°
Thickness >0.5mm Deep wall Ca2+
>2mm
>2mm Lumen
LMS or Ostial RCA
Bifurcation with buddy wire or >90° bend
Ca2+ Angle <180°
Ca2+ Angle >180°
<0.5°
Thickness <0.5mm Superficial Ca2+
>0.5°
Thickness >0.5mm Deep wall Ca2+
Further modification technique
Rota / Laser
NC / OPN / Scoring Balloons Cutting balloon
Rota Orbital
Shockwave
NC / OPN / Scoring Balloons Cutting balloon
Shockwave
No modification
Imaging
Ca2+ fracture
Yes - Ca2+ Modification
NC Balloon 1:1
80% stent expansion
IVUS >5.5mm2
OCT MSA >4.5mm2
LM >8mm2

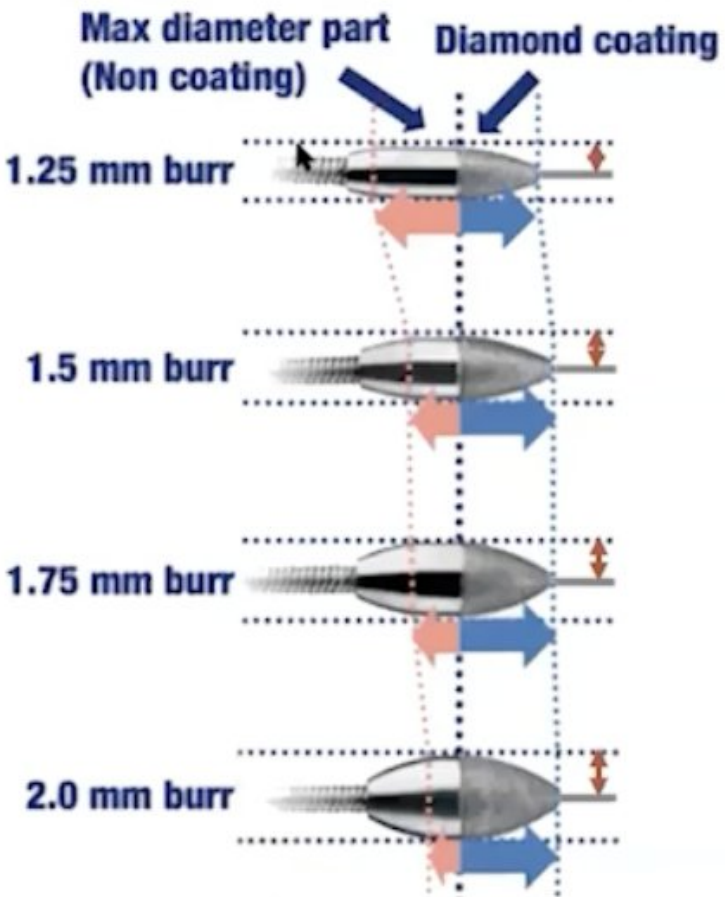

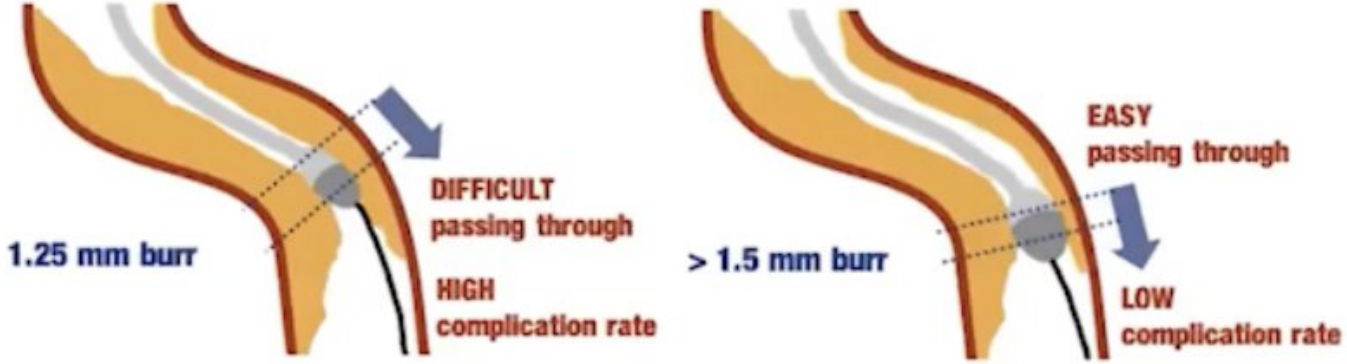

➤ The smaller the burr size, the longer the maximum diameter part. Therefore, the smaller burr easily goes to outward in this situation.

Burr Sizing – 0.5-0.75 of vessel diameter

The larger the burr the more favourable is the ratio
diamond-coated segment length / max diameter non coated segment length
Larger burr – less risk of entrapment

Patient level Meta-Analisi su 19,833 pazienti in 18 RCTs (1st and 2nd gen DES) e follow up medio 5 anni

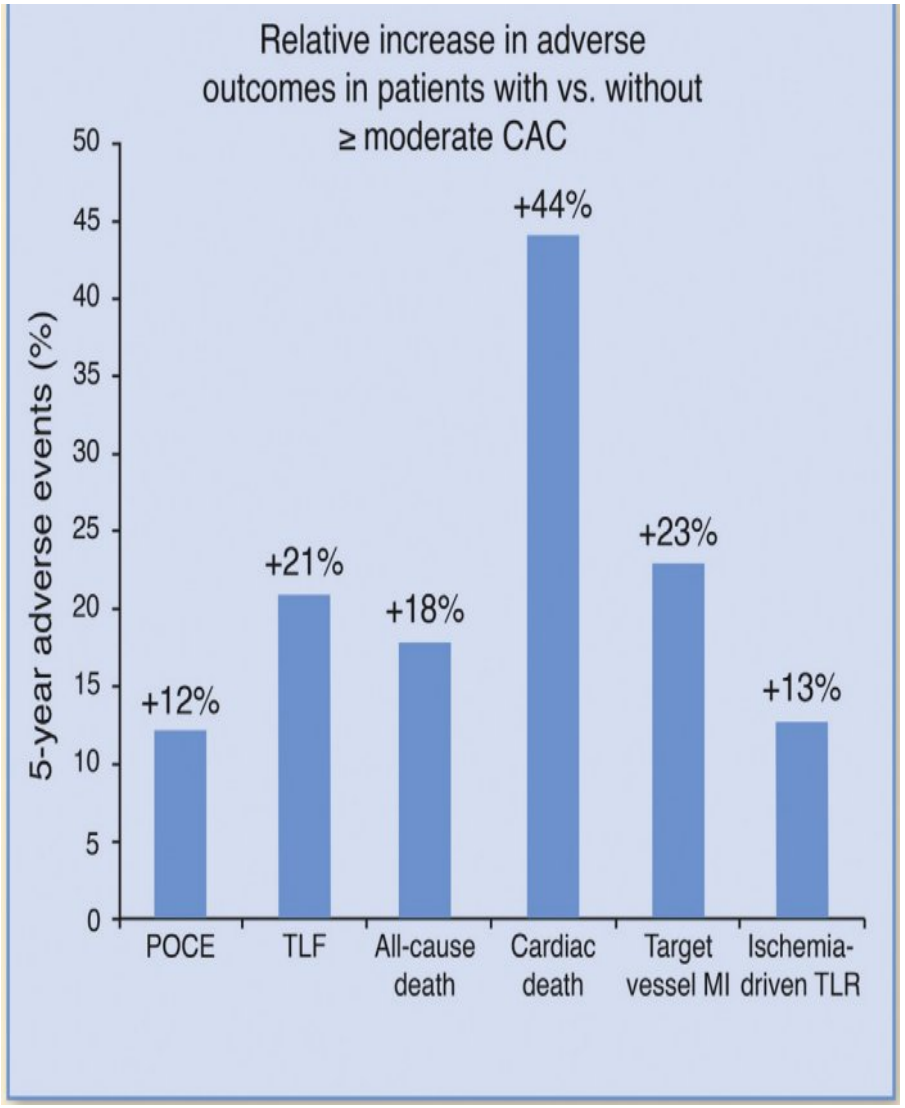

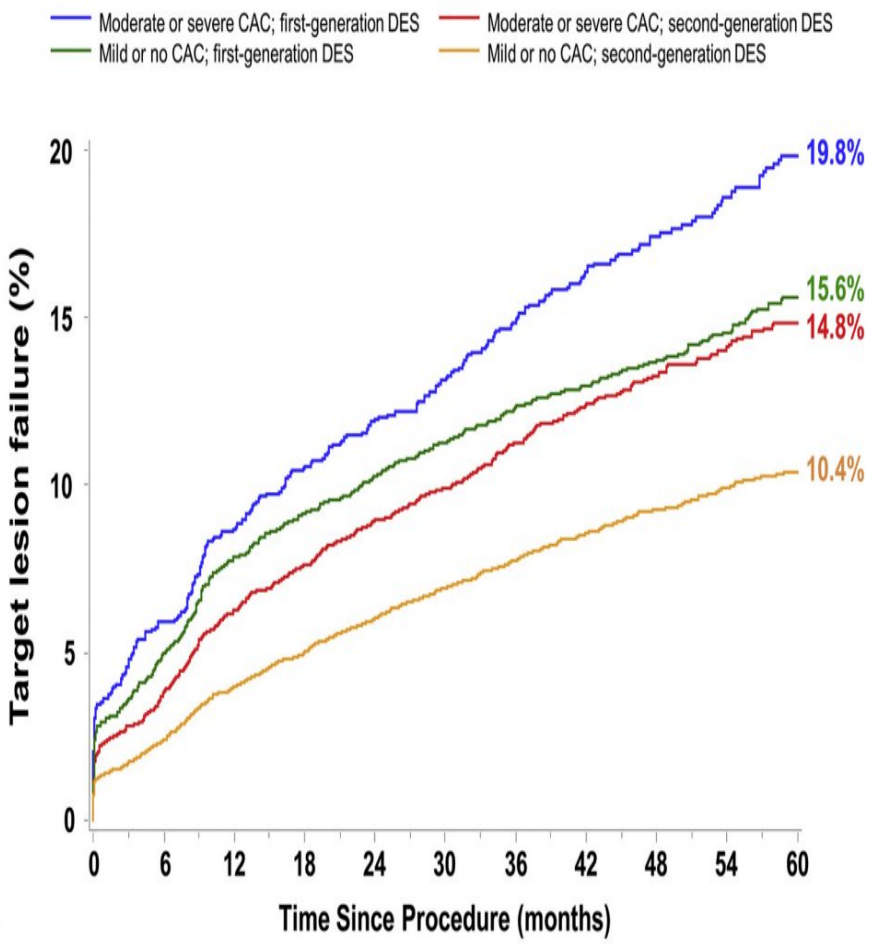

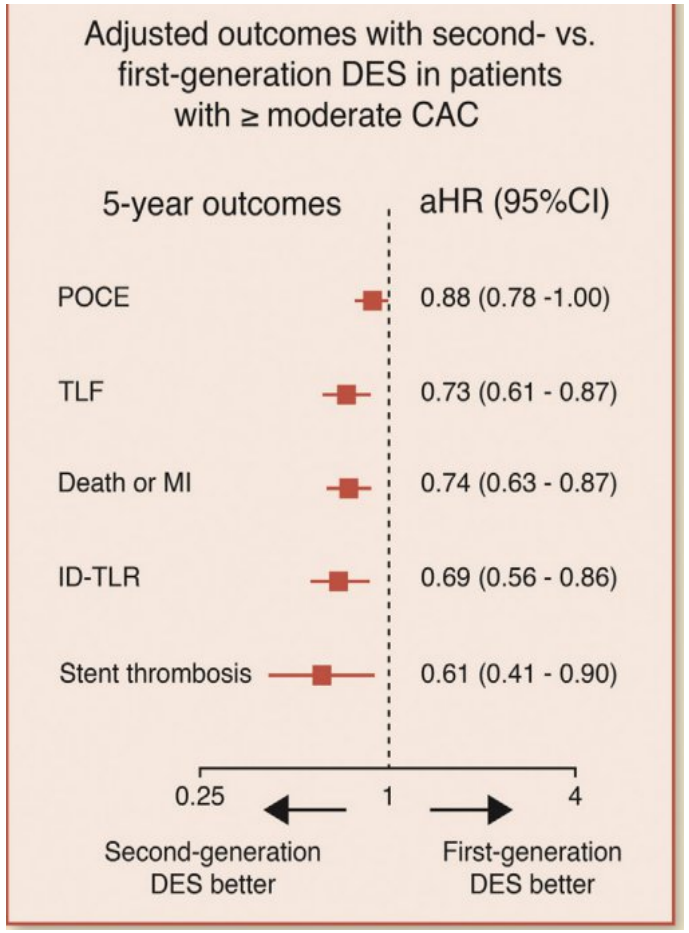

Guedeney P et al. JACC Intv 2020; 13: 1417 -1428